

Aspiration of an interesting foreign body: Myiasis

Emine İnce¹, Pelin Oğuzkurt¹, Hasan Özkan Gezer¹, Hikmet Eda Alışkan², Akgün Hiçsönmez¹

Departments of ¹Pediatric Surgery and ² Microbiology, Başkent University Faculty of Medicine, Ankara, Turkey.
E-mail: inceemine@yahoo.com

Received: 20 January 2015, Revised: 4 February 2015, Accepted: 25 February 2015

SUMMARY: İnce E, Oğuzkurt P, Gezer HÖ, Alışkan HE, Hiçsönmez A. Aspiration of an interesting foreign body: Myiasis. Turk J Pediatr 2015; 57: 621-623.

Myiasis is a rare condition caused by the invasion of tissues by the larvae of flies. Many cases of myiasis involving various human organs have been reported. Tracheopulmonary or intratracheal myiasis is a very unusual and aberrant form of the disease in humans. We present a case of respiratory myiasis after aspiration of larvae by a healthy 8-month-old girl, which cannot be found in the English literature.

Key words: myiasis, respiratory system, children, aspiration.

Myiasis, the invasion of live mammalian tissue by larvae of dipteran flies on the host's organs, body fluids or ingested food, may be specific, semi-specific or accidental. It is believed that the fly may even drop its eggs in flight on the skin, wounds or natural openings of an immobile person. Myiasis-producing larvae attack three main parts of the body: cutaneous tissue, body cavities and body organs^{1,2}. These larvae usually infest the ears, eyes and nose, as well as healthy or damaged skin¹⁻³. Nasal, oropharyngeal or orotracheal myiasis cases have been occasionally reported but tracheopulmonary or intratracheal myiasis is a very unusual and aberrant form of the disease in humans^{4,5}. In the present study, we report a case of respiratory myiasis caused by *Wohlfahrtia magnifica* in a child in whom myiasis aspiration with larvae proliferation at the respiratory epithelium was detected. We were unable to find such a case presented in the English literature.

Case Report

An 8-month-old girl was admitted to the emergency department with a sudden onset of coughing and wheezing. In her medical history, her parents noticed that she had spat out a housefly after coughing. Nasal discharge and coarse crackles were noted during the physical examination. There were nasal discharge and coarse crackles in physical examination.

Haematological investigations were normal. Total IgE was 0.6 IU/ml. The chest X-ray was normal. A bronchoscopy was performed with a probable diagnosis of foreign body aspiration of myiasis (Fig. 1). There were mucoid secretions and live larvae at the left lower bronchus. The bronchus was washed with normal saline and aspirated. Sample material in which larvae were seen was obtained from aspiration investigated by the microbiological department (Fig. 2). Albendazol treatment was started. Every third day, a bronchoscopy was performed and the bronchi were washed with saline and aspirated. The purpose of repeating the bronchoscopy was to clear the airway and reduce the larvae count. In the third procedure, the larvae were found to be significantly reduced in number and inactive. A microbiological investigation showed that the larvae belonged to a species of myiasis. In the fourth procedure, only secretion was found and the larvae were all cleared from the trachea and bronchi. The patient was followed routinely in case of possible respiratory complications.

Discussion

Myiasis due to *Wohlfahrtia magnifica* is very rare in childhood³. To our knowledge, this is the first case of respiratory myiasis in a healthy child.

Flies causing myiasis belong to the family of Diptera and its seven different species (Calliphoridae, Sarcophagidae, Oestridae,

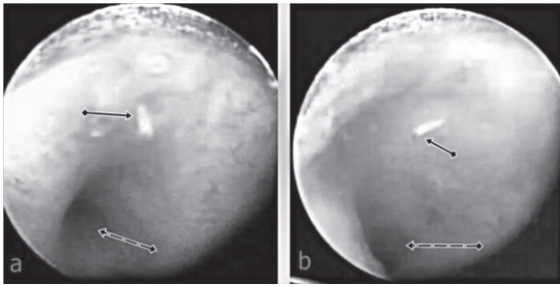


Fig. 1. Images of larva (black arrow) and left bronchi (dashed arrow) taken during bronchoscopy

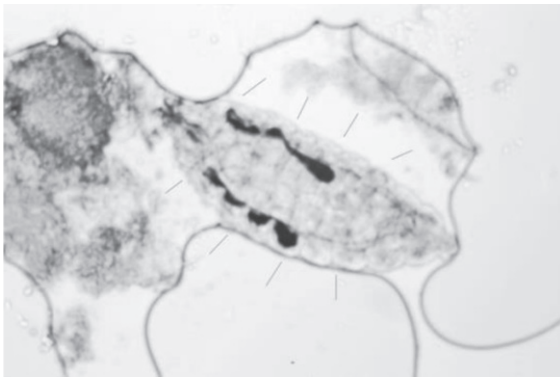


Fig. 2. Larvae version (between the arrows) detailed by microbiology department (HEEx40)

Hypodermatidae, Gasterophylidae, Glossinidae, and Muscidae) are known to invade the skin and body cavities, such as the nasal fossae and ears, and cause odoriferous discharge⁶. Among Calliphoridae and Sarcophagidae, most species that cause myiasis, deposit their eggs or larvae directly onto the host at some predisposing site, such as one caused by wounding, necrosis or bacterial contamination³.

Healthy hosts are much less attractive, even for obligate species such as *Wohlfahrtia magnifica*, which can attack healthy tissue. Advanced age, poor social conditions, mental retardation, immobilization, diabetes mellitus, alcoholism, vascular occlusive disease and infected dermatitis are predisposing factors for cutaneous myiasis^{1-4,6,7}. Our patient had no predisposing factors.

Myiasis is diagnosed by finding living fly maggots in various parts of the human body³. Tracheopulmonary myiasis is a rare manifestation of myiasis, with few published cases^{4,5,8}. One of which reported by Komori et al⁸. They presented a case of a 19-year-old Japanese man in good health was found on a routine chest X-ray to have considerable lung

abnormalities. After an open lung biopsy the patient was diagnosed as myiasis with 30 third-instar larvae of *Megaselia spiracularis* Schmitz which were seen in the suction tube postoperatively⁸. Chest auscultation and chest X-ray performed were normal shortly after our patient had spat out a housefly with coughing. Sudden onset of respiratory problems led us to evaluate the airway by bronchoscope, which led to the diagnosis.

The traditional treatment of myiasis is the mechanical removal of the maggots. When there are multiple larvae in advanced stages of development and tissue destruction, local application of several substances such as ethyl chloride, ether, chloroform, olive oil, calomel, iodoform, phenol and saline are used to ensure complete removal of all larvae⁵. We preferred to use a saline solution for washing out. We aimed to dilute the larvae, which were numerous, quite small and could not be grasped with clinical forceps by repeated bronchoscopy. Every third day, a bronchoscopy was performed and the bronchi were washed with saline and aspirated. The purpose of repeating the bronchoscopy was to clear the airway and reduce the larvae count. In the third procedure, the larvae were found to be significantly reduced in number. In the fourth procedure, only secretion was found and the larvae were all cleared from the trachea and bronchi.

The aspiration of myiasis and proliferation of larvae at the bronchi and trachea is a very rare type of foreign body aspiration. The purpose of treatment through repeated bronchoscopy, saline wash and aspiration was to clear the larvae without any damage to the respiratory epithelium and this treatment was successful in this subject.

REFERENCES

1. Ciftcioglu N, Altintas K, Haberal M. A case of human orotracheal myiasis caused by *Wohlfahrtia magnifica*. *Parasitol Res* 1997; 83: 34-36.
2. Yildirim I, Ceyhan M, Cengiz AB, Saki CE, Ozer E, Serdar B, Cilsal E. What's eating you? Cutaneous myiasis (*Wohlfahrtia magnifica*). *Cutis* 2008; 82: 396-398.
3. Tuygun N, Taylan-Ozkan A, Tanir G, Mumcuoglu KY. Furuncular myiasis in a child caused by *Wohlfahrtia magnifica* (Diptera: Sarcophagidae) associated with eosinophilia. *Turk J Pediatr* 2009; 51: 279-281.

4. Cornet M, Florent M, Lefebvre A, Wertheimer C, Perez-Eid C, Bangs MJ, Bouvet A. Tracheopulmonary myiasis caused by a mature third-instar *Cuterebra* larva: case report and review. *J Clin Microbiol* 2003; 41: 5810-5812.
5. Garrison RD. Human tracheopulmonary myiasis. *J Clin Microbiol* 2004; 42: 3378.
6. Büyükkurt MC, Miloğlu Ö, Nalbantoğlu S, Uslu H, Yolcu Ü, Aktaş O. Oral myiasis in a child due to *Wohlfahrtia magnifica*: original image. *Turkiye Klinikleri J Med Sci* 2008; 28: 782-785.
7. Raffaldi I, Scolfaro C, Pinon M, Longo S, Savoia D, Tovo PA. A strange gingival swelling in an Italian child: a case of oral myiasis. *Infez Med* 2013; 21: 56-59.
8. Komori K, Hara K, Smith KG, Oda T, Karamine D. A case of lung myiasis caused by larvae of *Megaselia spiracularis* Schmitz (Diptera: Phoridae). *Trans R Soc Trop Med Hyg* 1978; 72: 467-470.