

Scabies mimicking mastocytosis in two infants

Emine Çölgeçen-Özel¹, Ragıp Ertaş², Serap Utaş³, Olgun Konaş⁴

¹Department of Dermatology, Bozok University Faculty of Medicine, Yozgat, and Departments of ²Dermatology, and ⁴Pathology, Erciyes University Faculty of Medicine, Kayseri, and ³Department of Dermatology, Acıbadem Fulya Hospital, İstanbul, Turkey. E-mail: drecolgecen@hotmail.com

SUMMARY: Çölgeçen-Özel E, Ertaş R, Utaş S, Konaş O. Scabies mimicking mastocytosis in two infants. Turk J Pediatr 2013; 55: 533-535.

Scabies is a common parasitic human infection in infants and children. However, diagnostic pitfalls are frequent in infants, in whom the clinical presentation is usually atypical and different from that in adults. In nodular scabies, lesions may be clinically or histologically misdiagnosed as Langerhans cell histiocytosis, insect bite reaction, non-Langerhans cell histiocytosis, lymphoma, or urticaria pigmentosa.

We report two misleading cases of young infants (10- and 12-month-old infants) who presented with pruritic brown-red lesions on their trunks and showing a positive Darier's sign, suggestive of urticaria pigmentosa.

Key words: scabies, mastocytosis, infant.

Scabies can present with unusual morphologies and can mimic other entities including mastocytosis. Herein, we report the cases of two young infants with scabies masquerading as urticaria pigmentosa, both of whom were diagnosed following histopathological examination.

Case Reports

Case 1

A 10-month-old boy was referred for a pruritic rash. His mother reported a history of itchy erythematous macules and papules on the trunk and limbs, which had been present for one month. Personal and family medical histories were unremarkable. Topical steroids had been previously initiated for a presumptive diagnosis of eczema. The physical examination showed many red-brown macules and papules located on the trunk (Fig. 1). The scratching of a lesion induced a linear urticarial plaque, indicating a positive Darier's sign. A biopsy of the lesion was performed, and the diagnosis was urticaria pigmentosa. Routine laboratory tests were within normal limits, with the exception of lymphocytes (55.9%) and eosinophils (4.2%) in the peripheral blood. The rest of the physical examination was unremarkable.

The pathological examination showed hyperkeratosis and epidermal hyperplasia. There was a lifting of the stratum corneum, and

burrows were seen. Some parts of the parasite were seen in the burrows. There was also eosinophil-rich mixed inflammatory infiltrate in the superficial and middle dermis (Fig. 2).

Permethrin 5% cream was prescribed to the patient and his parents. After two weeks, with the second application of permethrin cream, the lesions had improved.

Case 2

A 12-month-old boy presented with a complaint of itchy lesions on his trunk, which had been present for three months. The lesions became more visible immediately after bathing. On the physical examination, there were many brown-red nodules on the trunk and back (Fig. 3). The Darier's sign was positive. Nodular urticaria pigmentosa was diagnosed clinically, and a skin biopsy demonstrated a crust at the top of the epidermis. There were small parts of parasites and severe inflammatory infiltrate and exudate in the hyperkeratotic crust. Eosinophil-rich mixed inflammatory cells were observed in the dermal perivascular areas (Fig. 4).

The infant's parents had denied knowledge of past dermatologic diseases during the first visit. However, they later recalled a history of family treatment for scabies six months earlier. The patient had not received treatment at that time. Topical benzyl benzoate and oral antihistamine allowed clearance of the lesions within a few weeks.

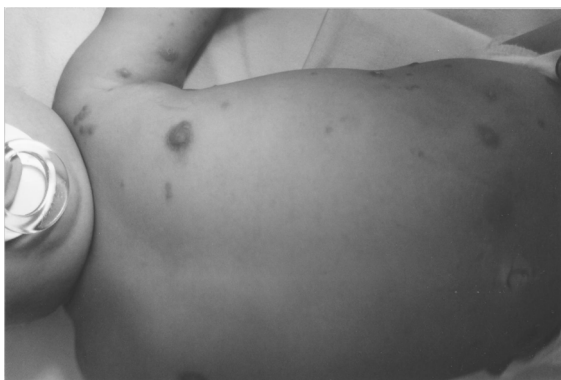

Fig. 1. Multiple red-brown macules and papules on the trunk of a 10-month-old child.

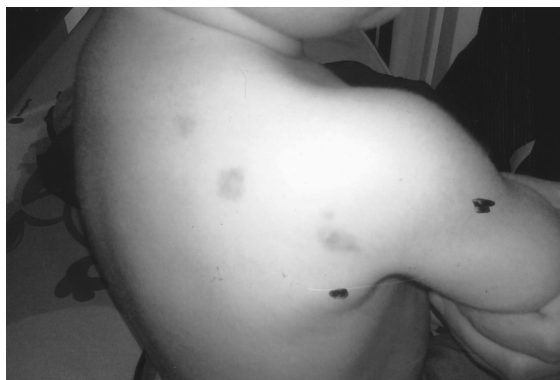

Fig. 3. The red-brown nodules on the back of a 12-month-old child.

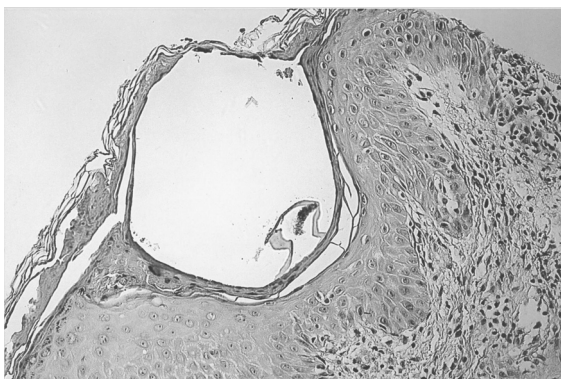


Fig. 2. The tunnel in the stratum corneum and the view of the parasite in the epidermal side of the tunnel (hematoxylin and eosin [HE], x200).

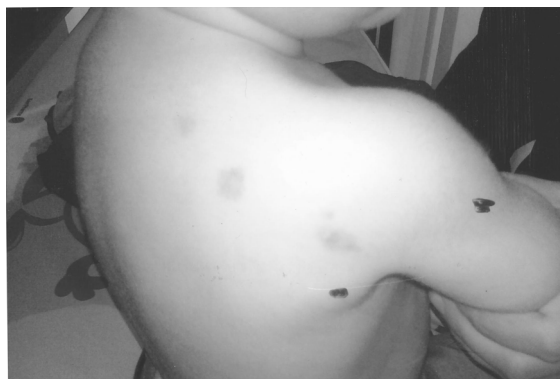

Fig. 4. Neutrophil leukocytes in the stratum corneum, small parts of parasites, and exudate in the hyperkeratotic crust (HE, x200).

Discussion

The prevalence of scabies is high in infants and children under two years. However, diagnostic pitfalls are common in infants because of a low index of suspicion, secondary eczematous changes, and inappropriate therapies, especially topical steroids. Several reports have emphasized that scabies in infants may mimic other skin diseases including bullous pemphigoid, Langerhans cell histiocytosis, lupus erythematosus, psoriasis, adverse drug reactions, lymphomatoid papulosis, or insect bite reaction. Three cases of urticaria pigmentosa-like scabies and a case of solitary mastocytoma have also been reported in the literature. Most of these were diagnosed without difficulty by histopathologic examination, and the first clinical diagnosis was urticaria pigmentosa. In mastocytosis pruritus, swelling and erythema may occur spontaneously after thermal, mechanical or chemical stimuli. In our

second case, the mother noticed itch and flare after bathing, possibly triggered by thermal and frictional stimuli. This characteristic, associated with a positive Darier's sign, led to an incorrect diagnosis. In addition, the palms, soles, face, and scalp are the frequently involved sites of infantile scabies, and these were lesion-free in our cases. However, urticaria pigmentosa is more frequently observed as red-brown macules, papules and sometimes as nodules and plaques over the trunk.

The increased number of mast cells in scabietic nodules may play a role in their pathogenesis and could be the cause of the positive Darier's sign. However, in our cases, we did not find a significant increase in the mast cell count upon staining with either hematoxylin and eosin or toluidine blue. Our positive Darier's sign cannot be explained by the presence of mast cells. In mastocytosis, the infiltrate is composed chiefly of mast cells and small numbers of

eosinophils, although prominent eosinophilic infiltration can be seen rarely.

Our observation shows that scabietic lesions may include brown-red macules and nodules mimicking urticaria pigmentosa. Darier's sign is not pathognomonic of mastocytosis. In nodular scabies, lesions may be clinically or histologically misdiagnosed as Langerhans cell histiocytosis, insect bite reaction, non-Langerhans cell histiocytosis, lymphoma, or urticaria pigmentosa. Scabies should be included in the differential diagnosis of urticaria pigmentosa. We suggest that a detailed family history should be taken in all pediatric patients with a skin disease.

REFERENCES

1. Kim KJ, Roh KH, Choi JH, Sung KJ, Moon KC, Koh JK. Scabies incognito presenting as urticaria pigmentosa in an infant. *Pediatr Dermatol* 2002; 19: 409-411.
2. Phan A, Dalle S, Balme B, Thomas L. Scabies with clinical features and positive darier sign mimicking mastocytosis. *Pediatr Dermatol* 2009; 26: 363-364.
3. Parodi A, Saino M, Rebora A. Bullous pemphigoid-like scabies. *Clin Exp Dermatol* 1993; 18: 393.
4. Burch J, Krol A, Weston W. *Sarcoptes scabiei* infestation misdiagnosed and treated as Langerhans cell histiocytosis. *Pediatr Dermatol* 2004; 21: 58-62.
5. Bastian HM, Lindgren AM, Alarcon GS. Scabies mimicking systemic lupus erythematosus. *Am J Med* 1997; 102: 305-306.
6. Mauleón-Fernandez C, Sáez-de-Ocariz M, Rodríguez-Jurado R, Durán-McKinster C, Orozco-Covarrubias L, Ruiz-Maldonado R. Nodular scabies mimicking urticaria pigmentosa in an infant. *Clin Exp Dermatol* 2005; 30: 595-596.
7. Salces IG, Alfaro J, Sáenz DE, Santamaría MC, Sanchez M. Scabies presenting as solitary mastocytoma-like eruption in an infant. *Pediatr Dermatol* 2009; 26: 486-488.
8. Amer M, Mostafa FF, Nasr AN, el-Harras M. The role of mast cells in treatment of scabies. *Int J Dermatol* 1995; 34: 186-189.