

## Torsion of an epididymal cyst: a case report and review of the literature

Volkan Erikçi, Münevver Hoşgör, Melih Yıldız, Nail Aksoy, Özkan Okur, Yılmazcan Örnek, Yusuf Demircan

Department of Pediatric Surgery, Dr. Behçet Uz Children's Hospital, İzmir, Turkey. E-mail:verikci@yahoo.com

**SUMMARY:** Erikçi V, Hoşgör M, Yıldız M, Aksoy N, Okur Ö, Örnek Y, Demircan Y. Torsion of an epididymal cyst: a case report and review of the literature. Turk J Pediatr 2013; 55: 659-661.

Torsion of an epididymal cyst (EC) on its pedicle is an extremely rare condition that resembles acute testicular torsion. Herein, a boy with EC torsion managed surgically is presented and discussed in light of the relevant literature. The presented child is probably the fourth case of pediatric EC torsion, and to our knowledge, the first report of a child who was known to have EC and was followed conservatively until the occurrence of EC torsion.

**Key words:** testis, epididymal cyst, torsion.

Epididymal cysts (EC) in children and adolescents are usually benign lesions diagnosed during evaluation of scrotal pain or mass by ultrasound (US). Varying rates of EC in children are reported in the literature, ranging from 5% to as high as 20%<sup>1-3</sup>. Though the etiology of EC is not known clearly, it is probably a congenital abnormality related to hormonal disorders during embryonic life<sup>4-8</sup>. Conservative management in children with EC has been suggested in most, leaving surgical cyst excision for a minority of patients<sup>9,10</sup>.

Torsion of an EC is extremely rare, and to our knowledge, only three children with EC torsion have been reported in the literature previously. In this report, an 11-year-old boy with EC torsion is presented and discussed with regard to the related literature.

### Case Report

An 11-year-old boy was admitted to our department with the symptoms of acute scrotum. In addition to the physical examination, diagnosis of left EC with a diameter of 3 mm was confirmed with scrotal Doppler US by observing an echo-free cystic structure within the epididymis with no perfusion (Fig. 1). Both testes were found to have normal parenchymal architecture and echogenicity with no perfusion defect. Conservative management with semiannual US was planned. In the 12<sup>th</sup>

follow-up month, he presented with a scrotal pain intensity that resembled acute testicular torsion, and he was admitted to the hospital. His physical examination revealed an extremely tender left testis and epididymis. Laboratory and biochemical investigations were otherwise normal. Scrotal Doppler US depicted two testes equal in size (right: 40x19 mm; left: 38x19 mm) with homogeneous arterial perfusion. There was an EC of 4 mm located in the left caput epididymis and bilateral minimal hydrocele. Because the intensity of the scrotal pain increased and could not be controlled medically, with a diagnosis of acute scrotum, a prompt surgical intervention was performed. During the operation, the left testis was seen as normal. An EC of 4 mm in diameter was found within the caput epididymis torsed 720° clockwise on its own pedicle (Fig. 2). Detorsion and excision of the EC were performed. The histopathological diagnosis was EC with no necrosis in the cells of the epididymal duct. The patient was discharged from the hospital on the second postoperative day. After the first postoperative year, there has been no recurrence.

### Discussion

Acute scrotal conditions are common in children. They present with scrotal pain, swelling and sometimes redness in the affected hemiscrotum. The true cause is difficult to

determine. There are a myriad of etiologies for this syndrome, but most common are torsion of the testis, torsion of the testicular appendix, epididymo-orchitis, and strangulated inguinoscrotal hernia<sup>11-13</sup>.

Smooth, extratesticular cysts in the epididymis are not uncommon in adult men and usually develop in adults around the age of 40<sup>10</sup>. The incidence of ECs in children ranges from 5% to 20%<sup>1-3</sup>. Whether these cysts are degenerative in nature or the result of endocrine-disrupting agents acting fetally or postnatally is not known with certainty, and the functional significance of EC is also unclear<sup>9,14</sup>. In the majority of patients with EC, conservative management has been suggested<sup>9</sup>.

As a cause of acute scrotum, torsion of an EC is an extremely rare condition and has not been well characterized. The first pediatric case of EC torsion was a 13-year-old boy with a 360°

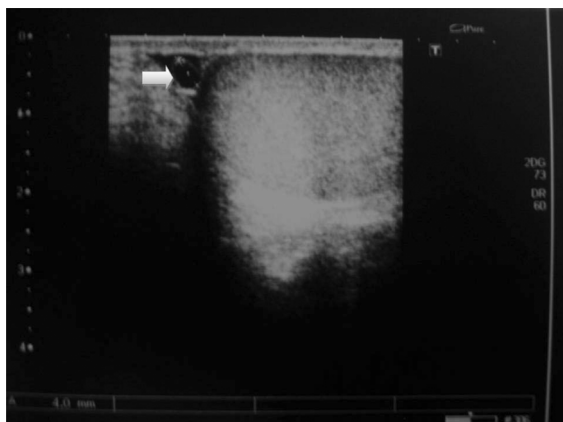


Fig. 1. Scrotal US of a patient with EC (Arrow: epididymal cyst).

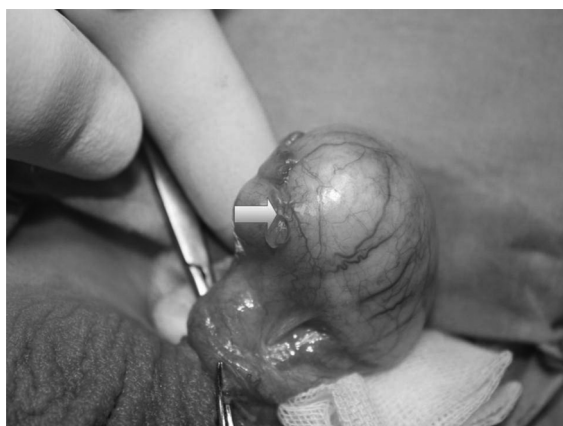

Fig. 2. Intraoperative view of a patient with torsion of EC (Arrow: epididymal cyst).

left EC torsion, and the torted cyst was excised with a trans-inguinal approach<sup>15</sup>. The second case of EC torsion was in a six-month-old male<sup>16</sup>. Apart from aplasia of the vas deferens, surgical exploration of the baby revealed a 2 cm pedunculated cyst arising from the tail of the left epididymis, and the stalk was found to be twisted 360°. The third pediatric case of EC torsion was a 13-year-old boy with a history of scrotal trauma before admission to the hospital<sup>17</sup>. Surgical exploration of the left hemiscrotum showed a 720° medially-directed torsion of an EC, and histologically, the cells of the epididymal duct were found to be necrotic in that case<sup>16</sup>. The presented child in this study is probably the fourth case of pediatric EC torsion. To our knowledge, this is the first report of a child known to have EC previously who was followed conservatively until the occurrence of EC torsion. The histopathological examination revealed a 4 mm unilocular cyst covered by one layer of cuboidal epithelium, compatible with EC. No sperm cells were detected, and there was no necrosis in the cells of the epididymal duct. Reported cases in the literature and the current patient had torsion of ECs located within the left epididymis. To our knowledge, no cases of EC torsion within the right epididymis have been reported.

All the patients with torsion of EC, including our case, presented with symptoms related to acute scrotum, namely scrotal swelling and pain. Torsion of an EC should be considered in the differential diagnosis of acute scrotum in children ever known to have EC. In the case of occurrence, surgical excision of the torted EC becomes a matter of necessity rather than of choice since surgical excision promptly resolves the intractable scrotal pain produced by the torted EC.

#### REFERENCES

1. Finkelstein MS, Rosenberg HK, Snyder HM 3<sup>rd</sup>, et al. Ultrasound evaluation of scrotum in pediatrics. *Urology* 1986; 27: 1-9.
2. Rifkin MD, Kurt AB, Goldberg BB. Epididymis examined by ultrasound. Correlation with pathology. *Radiology* 1984; 151: 187-190.
3. Gill WB, Schumacher GF, Bibbo M, et al. Association of diethylstilbestrol exposure in utero with cryptorchidism, testicular hypoplasia and semen abnormalities. *J Urol* 1979; 122: 36-39.

4. Gill WB, Schumacher GF, Bibbo M. Pathological semen and anatomical abnormalities of the genital tract in human male subjects exposed to diethylstilbestrol in utero. *J Urol* 1977; 117: 477-480.
5. Atanassova N, McKinnell C, Turner KJ, et al. Comparative effects of neonatal exposure of male rats to potent and weak (environmental) estrogens on spermatogenesis at puberty and the relationship to adult testis size and fertility: evidence for stimulatory effects of low estrogen levels. *Endocrinology* 2000; 141: 3898-3907.
6. Bibbo M, Al-Naqeeb M, Baccarini I, et al. Follow-up study of male and female offspring of DES-related mothers. A preliminary report. *J Reprod Med* 1975; 15: 29-32.
7. Jones LA. Long-term effects of neonatal administration of estrogen and progesterone, alone or in combination, on male BALB/c and BALB/cfC3H mice (40927). *Proc Soc Exp Biol Med* 1980; 165: 17-25.
8. McLachlan JA. Prenatal exposure to diethylstilbestrol in mice: toxicological studies. *J Toxicol Environ Health* 1977; 2: 527-537.
9. Homayoon K, Suhre CD, Steinhardt GF. Epididymal cysts in children: natural history. *J Urol* 2004; 171: 1274-1276.
10. Chillon SF, Dominguez HC, Serrano DA, et al. Epididymal cysts in childhood. *Arch Esp Urol* 2005; 58: 325-328.
11. Sidler D, Brown RA, Millar AJ, et al. A 25-year review of the acute scrotum in children. *S Afr Med J* 1997; 87: 1696-1698.
12. Kaddish HA, Bolte RG. A retrospective review of pediatric patients with epididymitis, testicular torsion and torsion of testicular appendages. *Pediatrics* 1998; 102: 73-76.
13. Lewis AG, Bukowski TP, Jarvis PD, et al. Evaluation of acute scrotum in the emergency department. *J Pediatr Surg* 1995; 30: 277-282.
14. Steinhardt GF. Editorial comment to epididymal cysts: not always a benign condition. *Int J Urol* Sep 21, 2012; doi: 10.1111/j.1442-2042.2012.03177.
15. Kaye RI, Cromie WJ. Torsion of a spermatocele: a case report and review of the literature. *J Urol* 1990; 143: 786.
16. Liolios N, Anagnostopoulos D, Sinopidis X, et al. Torsion of spermatocele and aplasia of the vas deferens. A case report. *Eur J Pediatr Surg* 1997; 7: 118-119.
17. Yılmaz E, Batislam E, Bozdogan O, et al. Torsion of an epididymal cyst. *Int J Urol* 2004; 11: 182-183.