

Percutaneous retrieval of a chronic catheter fragment from the left ventricle in a child

Dolunay Gürses¹, A. Ruhi Özyürek², Ertürk Levent², Zülal Ülger²

Departments of Pediatrics, ¹Pamukkale University Faculty of Medicine, Denizli, and ²Ege University Faculty of Medicine, İzmir, Turkey

SUMMARY: Gürses D, Özyürek AR, Levent E, Ülger Z. Percutaneous retrieval of a chronic catheter fragment from the left ventricle in a child. *Turk J Pediatr* 2012; 54: 290-293.

Embolization of a catheter fragment is a very rarely seen complication, and few cases have been reported in children. Catheter fragments must be urgently extracted due to life-threatening complications. Most catheter fragments are removed very soon after being lost in the cardiovascular system, including the venous system and right side of the heart. In our report, we describe a child with catheter fragment, which was removed from the left ventricle 32 days after embolization. This catheter fragment was successfully retrieved percutaneously using a gooseneck snare catheter through the femoral artery.

Key words: left ventricle, percutaneous retrieval, gooseneck snare, childhood.

Intravascular and intracardiac embolization of catheter fragments is a very rarely seen serious complication, and few cases have been reported in children¹⁻⁶. Catheter fragments can cause complications such as thrombus formation and embolization. Serious complications, such as sepsis, cardiac perforation, arrhythmia, and death, have also been reported as a result of embolization of catheter fragments^{1,4}. In light of the potential for these serious complications, catheter fragments must be retrieved urgently. Before the percutaneous technique by snare-loop catheter, surgical removal had been used as the only method. Nowadays, most catheter fragments are removed soon after being lost in the cardiovascular system, including the venous system and right side of the heart, before causing any significant foreign body reaction or fibrin deposition^{1,3-7}. There are only a few reports related with retrieval of foreign bodies remaining in the cardiovascular system for a long period^{2,7}. There is no report in the literature of retrieval of the foreign body from the left ventricle in children.

We describe a child with a catheter fragment that was removed from the left ventricle 32 days after embolization. With this case report, we want to emphasize that retrieval of intracardiac or intravascular foreign bodies

with percutaneous technique should be the recommended treatment modality rather than surgical retrieval; catheters should be extracted from patients carefully.

Case Report

A five-year-old female patient with the diagnosis of pulmonary atresia admitted to our hospital for a routine outpatient clinic follow-up. She had no symptom at admission. We learned from her medical history that she was previously diagnosed as pulmonary atresia, patent ductus arteriosus (PDA), and patent foramen ovale, and PDA ligation and xenograft implantation on the pulmonary region had been applied at seven months of age. Thirty-two days before admission to our hospital, homograft implantation was applied in the pulmonary region due to xenograft dysfunction.

On the cardiovascular examination, 1/6 diastolic heart murmur was heard on the left second intercostal area. The other findings of the physical examination were unremarkable. Laboratory findings included hematocrit 43%, white blood cell count 8500/mm³ and erythrocyte sedimentation rate 22 mm/h, and C-reactive protein was negative. Renal and hepatic function tests were normal. Blood cultures were sterile. On electrocardiographic

examination, rhythm was sinus, and QRS axis was +90 degrees. The posterior-anterior and lateral chest X-ray showed prominent pulmonary conus, and radiopaque string appearance causing the suspicion of foreign body in the left ventricular cavity. In transthoracic echocardiography, echogenic mobile foreign body in the left ventricle extending to the aorta was observed. The foreign body was suspected to be a catheter fragment (Fig. 1). No thrombus was observed on the catheter fragment in transthoracic echocardiography. Tricuspid and pulmonary valve regurgitations were observed. Ventricle functions were normal. We were informed by the center in which the operation was performed that a catheter had been placed into the left atrium for invasive pressure monitoring. We thought that this detected foreign body in the left ventricle was probably a fragment of this previously placed left atrial pressure catheter.

This probable catheter fragment was also visualized under fluoroscopy (Fig. 2). The catheter fragment was retrieved via the right femoral artery, which was entered percutaneously with a 7 Fr sheath. We entered the left ventricle with the 5 Fr multipurpose catheter. A 10 mm nitinol gooseneck snare (Amplatz GooseNeck Snare, Microvena Corporation, White Bear Lake, MN, USA) was advanced to the left ventricle through the multipurpose catheter. The advancing snare was delivered to the left ventricle and the catheter fragment was caught with the snare (Fig. 3). The caught catheter fragment was retracted carefully and gently to the aorta from the left ventricle during the systole, and extracted easily via the 7 Fr

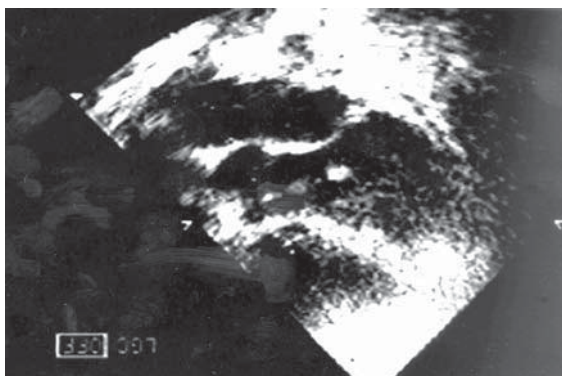


Figure 1. Transthoracic echocardiography demonstrates the echogenic mobile foreign body in the left ventricle extending to the aorta.

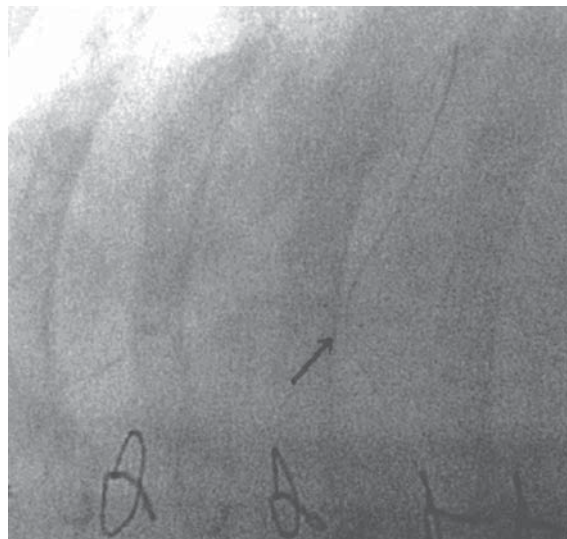


Figure 2. The catheter fragment was observed in the left ventricle under fluoroscopy.

sheath. The percutaneous retrieval procedure was successfully completed and no complication was observed related with the procedure. The percutaneously retrieved catheter fragment is shown in Figure 4. Two days after the procedure, the patient was discharged from the hospital symptom-free. The patient remained asymptomatic during the one-year follow-up.

Discussion

Intravascular and intracardiac embolization of catheter fragments is a serious and rare complication, and the incidence has been reported to range between 0-4.1% in adult

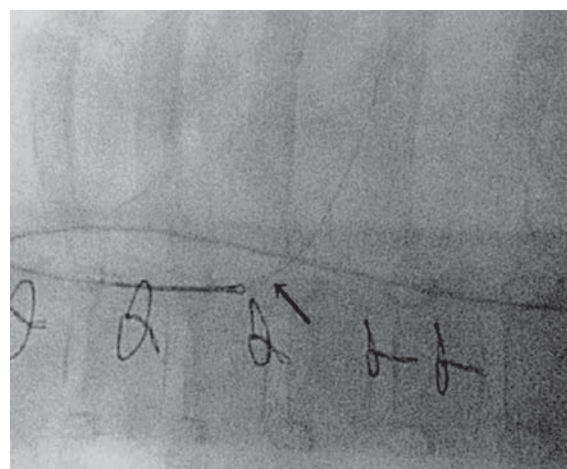


Figure 3. The catheter fragment was caught with the snare loop in the left ventricle.

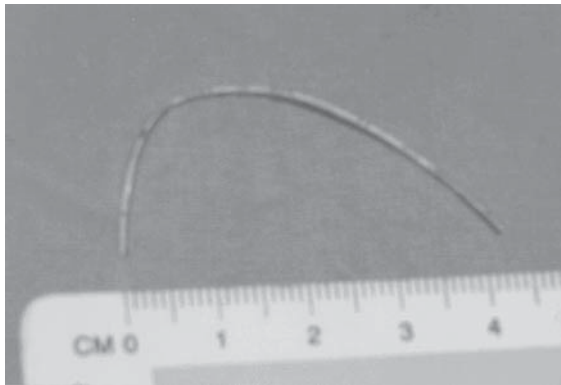


Figure 4. Image of the percutaneously retrieved foreign body.

patients⁸. Few cases have been reported in children, and the incidence is unknown¹⁻⁶. Many devices have been used for retrieval of intravascular foreign bodies, including snares, biopsy forceps, Dormia baskets, tip-deflecting wires, and balloon catheters⁹. Today, the loop-snare technique has been used in most of the cases as a primary choice due to the rather low complication rate when compared to the other techniques.

Most of the intravascular foreign bodies settle in the systemic veins, right atrium, right ventricle, pulmonary arteries, and left atrium via the patent foramen ovale, and are extracted from the femoral vein^{1-7,10}. An intra-arterial settled foreign body was reported in the literature, in an adult¹¹. However, foreign body in the left ventricle was not described previously, and our literature search revealed no previous case similar to ours. We thought that this condition might be related with the less frequently used intra-arterial applications compared to venous applications.

Intravascular foreign body retrieval in the acute setting (<24 hours [h]) is well described^{1,9}. Chronically retained intravascular foreign bodies, however, may be firmly lodged, fibrosed or endothelialized to the vessel wall, confounding efforts at retrieval. When the loss of catheter fragment was immediately recognized, the fragment was retrieved with a success rate exceeding 90%⁹. However, retrieval of chronically retained catheter fragments has shown variable success^{2,7}. The decision to retrieve an intravascular foreign body in the chronic stage was based on the risk of complication. There have been only a few

reports similar to our case that were related with percutaneous retrieval of chronically retained catheter fragments in children^{2,7}. Farrell et al.² retrieved catheter fragments percutaneously from the left atrium, pulmonary arteries and right ventricular outflow tract in three children several months after embolization. Similarly, we successfully retrieved a catheter fragment from the left ventricle one month after embolization. There was no problem or complication during the procedure and follow-up.

With this case report, we describe a child with catheter fragment that was removed from the left ventricle 32 days after embolization. To our knowledge, percutaneous retrieval of broken catheters from the left ventricle has not been described previously. This is the first description of such a therapeutic option for a foreign body lodged in the left ventricle in a child. We emphasize that great attention must be given during the retrieval of the catheter from the patient, and the entire body of the catheter must be carefully controlled.

REFERENCES

1. Herranz Jordan B, Bermudez-Canete Fernandez R, Herráiz Sarachaga JI, et al. Non-surgical extraction of intravascular foreign bodies in children. Experience with 8 cases. *Rev Esp Cardiol* 1995; 48: 326-332.
2. Farrell AG, Parikh SR, Darragh RK, Girod DA. Retrieval of old foreign bodies from the cardiovascular system in children. *Cathet Cardiovasc Diagn* 1998; 44: 212-216.
3. Andrews RE, Tulloh RM, Rigby ML. Percutaneous retrieval of central venous catheter fragments. *Arch Dis Child* 2002; 87: 149-150.
4. Bessoud B, de Baere T, Kuoch V, et al. Experience at a single institution with endovascular treatment of mechanical complications caused by implanted central venous access device in pediatric and adult patients. *AJR* 2003; 180: 527-532.
5. Uçar B, Kiliç Z, Ayata M, Tokar B, İlhan H. Percutaneous retrieval of an intracardiac catheter fragment using a snare-loop catheter. *Anadolu Kardiyol Derg* 2005; 5: 257.
6. Tutar E, Aypar E, Atalay S, Yavuz G, Doğu F. Percutaneous transcatheter retrieval of intracardiac central venous catheter fragments in two infants using Amplatz Goose Neck snare. *Turk J Pediatr* 2009; 51: 519-523.
7. Savage C, Ozkan OS, Walser EM, Wang D, Zwischenberger JB. Percutaneous retrieval of chronic intravascular foreign bodies. *Cardiovasc Intervent Radiol* 2003; 26: 440-442.
8. Cheng CC, Tsai TN, Yang CC, Han CL. Percutaneous retrieval of dislodged totally implantable central venous access system in 92 cases: experience in a single hospital. *Eur J Radiol* 2009; 69: 346-350.

9. Gabelmann A, Kramer S, Gorich J. Percutaneous retrieval of lost or misplaced intravascular objects. *AJR* 2001; 176: 1509-1513.
10. Ramondo AB, Favero L, Chioin R. Percutaneous retrieval of broken catheter from the left atrium in an adult. *J Interv Cardiol* 2002; 15: 417-420.
11. Yılmaz H, Belgi A, Demir I, Başarıcı I, Sancaktar O. Successful transcatheter retrieval of an embolized stent from the left ventricle. *J Invasive Cardiol* 2002; 14: 466-468.