

## Pseudo-trisomy 13 in a fetus: further support for autosomal recessive inheritance

G. Eda Utine<sup>1</sup>, Yasemin Alanay<sup>1</sup>, Dilek Aktaş<sup>1</sup>, Beril Talim<sup>2</sup>

Gülsev Kale<sup>2</sup>, Ergül Tunçbilek<sup>1</sup>

Units of <sup>1</sup>Genetics, and <sup>2</sup>Pathology, Department of Pediatrics, Hacettepe University Faculty of Medicine, Ankara, Turkey

**SUMMARY:** Utine GE, Alanay Y, Aktaş D, Talim B, Kale G, Tunçbilek E. Pseudo-trisomy 13 in a fetus: further support for autosomal recessive inheritance. Turk J Pediatr 2008; 50: 287-290.

Pseudo-trisomy 13 is defined in chromosomally normal patients with holoprosencephaly and associating features suggestive of trisomy 13. An autosomal recessive pattern of inheritance for this situation is most likely, but a gene for this condition has not yet been mapped. A fetus is presented with phenotypic features reminiscent of trisomy 13 but a normal karyotype, 46, XY. The pregnancy was terminated due to severe fetal malformations. In autopsy, the fetus had semilobar holoprosencephaly, hydrocephaly and dysmorphic features such as hypotelorism, cleft lip, a flat nose with a single nostril, low-set ears, postaxial polydactyly in all extremities, left unilateral pes equinovarus and pulmonary segmentation defect on the right. The parents were 2<sup>nd</sup> cousins once removed. Holoprosencephaly and polydactyly with or without other findings in chromosomally normal patients should raise the suspicion of pseudo-trisomy 13 syndrome, particularly when parental consanguinity is present.

**Key words:** trisomy 13, pseudo-trisomy 13, holoprosencephaly, polydactyly.

Holoprosencephaly results from failure of midline cleavage of the developing prosencephalon. Midline and paramedian structures in the floor of the forebrain may be absent and severe holoprosencephaly may inhibit further development of the brain. The prevalence is 1.2 in 10,000 among live births and fetal deaths<sup>1</sup>.

The genetic basis underlying holoprosencephaly is incompletely elucidated. Approximately 50% of all holoprosencephaly cases have either a cytogenetic anomaly or a monogenic syndrome<sup>1</sup>. Overall, trisomy 13 is responsible for 40% of the cases with holoprosencephaly<sup>2</sup>, but a number of other chromosome imbalances<sup>1</sup> may be causative as well. Holoprosencephaly may be a component of 95 different conditions described in the London Medical Database, and mutations in several genes may be responsible for isolated occurrence of holoprosencephaly<sup>3</sup>. Maternal exposure to certain drugs, alcohol, cigarette smoking and maternal insulin-dependent diabetes were reported to be associated with holoprosencephaly as well<sup>4</sup>. However, assigning a cause may be impossible for a significant number of cases<sup>1,4,5</sup>.

Pseudo-trisomy 13 was first defined in 1991 by Cohen and Gorlin<sup>6</sup> in chromosomally normal patients with holoprosencephaly and associating features suggestive of trisomy 13. An autosomal recessive pattern of inheritance for this situation seems most likely, but a gene has not yet been mapped. Herein, a fetus with phenotypic features highly suggestive of trisomy 13 and a normal karyotype is presented, in whom further support for an autosomal recessive inheritance pattern is provided by parental consanguinity.

### Case Report

A 24-year-old pregnant woman was referred to the Genetics Unit at the 16<sup>th</sup> gestational week on detection of fetal abnormalities on obstetric ultrasound. Findings included semilobar holoprosencephaly, ventriculomegaly, choroid plexus cyst, left ventricular hypoplasia and ventricular septal defect. The parents were 2<sup>nd</sup> cousins once removed. The first pregnancy had ended in a first trimester abortus.

Cytogenetic analysis in 50 GTG-banded metaphase spreads prepared from amniocytes after standard culture and chromosome

preparation techniques yielded a normal karyotype 46, XY. Based on sonographic findings, the parents decided to terminate the pregnancy and the fetus was delivered at the 16<sup>th</sup> gestational week. An autopsy was performed. It was a male fetus whose growth was appropriate for gestational age: body weight was 109 g (N:  $108 \pm 25$ ), crown-rump distance was 12 cm (N:  $12 \pm 1.1$ ) and toe-heel distance was 2.5 cm (N:  $2.1 \pm 0.2$ ). He had dysmorphic features such as hypotelorism, central cleft lip, a flat nose with a single nostril and low-set ears (Fig. 1). There was postaxial polydactyly with six fingers in all four extremities, clinodactyly of the 6<sup>th</sup> fingers and left pes equinovarus (Fig. 2). The halluces were wide, but not bifid, and the X-ray was normal. Central nervous system investigation revealed semilobar holoprosencephaly with severe hydrocephaly (Fig. 3). Heart was normal with intact interventricular septum. An additional finding was the presence of two lobes in the right lung.

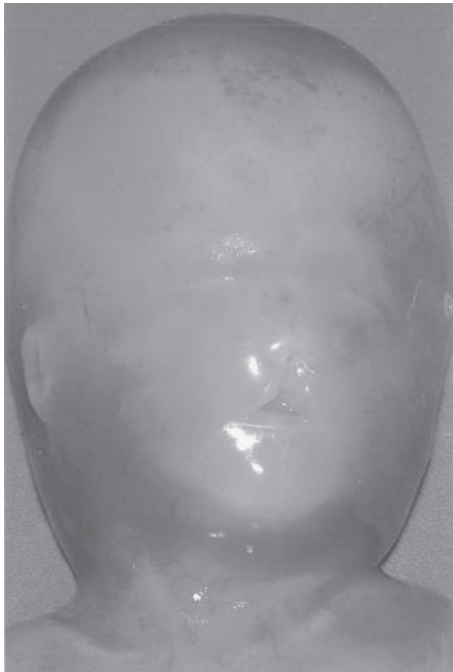

Fig. 1. The face of the fetus with hypotelorism, cleft lip, flat nose with a single nostril and low-set ears.

Parental karyotypes, performed on GTG-banded metaphase spreads prepared from phytohemagglutinin (PHA)-stimulated peripheral blood lymphocytes after standard culture and chromosome preparation techniques were normal.

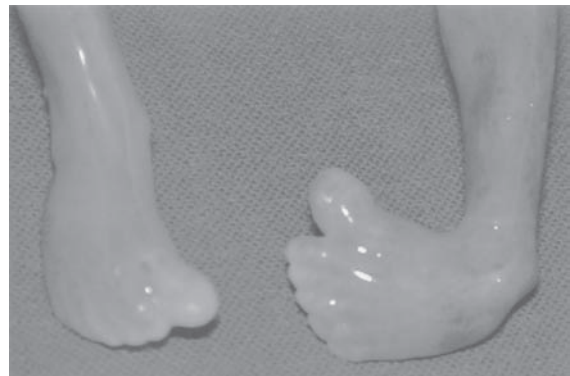

Fig. 2. Postaxial polydactyly and left pes equinovarus.

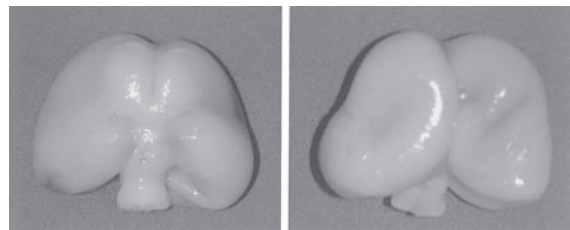


Fig. 3. Anterior (a) and posterior (b) views of the brain showing fusion of two cerebral hemispheres in the frontal region and two separate hemispheres in the posterior. In (b), inward folding of the hemispheres due to hydrocephaly is seen.

## Discussion

Pseudo-trisomy 13 was defined by Cohen and Gorlin in 1991<sup>6</sup> in 11 chromosomally normal patients with phenotypic findings highly suggestive of trisomy 13. The patients had holoprosencephaly, postaxial polydactyly and facial abnormalities, and various other congenital defects. The patient previously reported by Young and Madders in 1987<sup>7</sup> was retrospectively considered to have this condition. This stillborn baby had alobar holoprosencephaly, ventricular septal defect, atrial septal defect, premaxillary agenesis, postaxial polydactyly of the hands, microphthalmos, a small penis and cryptorchidism. This clinical presentation was reminiscent of trisomy 13 but the karyotype was normal. At least 50 other patients have been reported since then.

By definition, clinical criteria sufficient for a diagnosis of pseudo-trisomy 13 syndrome require a combination of features suggestive of trisomy 13 in the absence of a chromosomal abnormality. A typical presentation of patients with trisomy 13 includes postaxial polydactyly

plus any combination of microcephaly, ocular malformation, cleft lip/cleft palate, heart defect and renal anomalies, and if polydactyly is absent, presence of scalp defects is considered helpful<sup>8</sup>. For pseudo-trisomy 13, the minimal diagnostic criteria are not well established. Holoprosencephaly and polydactyly seem to be the most consistent findings for the condition<sup>9</sup>, but not all patients have polydactyly<sup>10</sup>. Each of these two findings was found in only 60% of affected patients<sup>11</sup>. As diagnostic criteria, a normal karyotype plus presence of one of the following was suggested as minimum requirements<sup>11</sup>: (1) a combination of holoprosencephaly and post-axial polydactyly with or without other characteristics, (2) a combination of holoprosencephaly with other characteristics but without polydactyly, or (3) a combination of post-axial polydactyly, brain defects (microcephaly, hydrocephaly, agenesis of corpus callosum) and other characteristics.

The fetus we present had a combination of holoprosencephaly and post-axial polydactyly without other characteristics, therefore meeting the first criteria. Parental consanguinity and overlapping clinical features might have been suggestive of hydroletharus syndrome, Meckel syndrome, Pallister-Hall syndrome and Smith-Lemli-Opitz syndrome; however, these were considered less likely diagnoses since other typical features of these conditions were

absent. Hydroletharus syndrome was ruled out due to the absence of major features, including polyhydramnios, severe prenatal onset hydrocephalus, micrognathia, small and deep-set eyes, hypertelorism and a typical “keyhole” occipital bone defect. A diagnosis of Meckel syndrome requires posterior encephalocele and cystic dysplastic kidneys, which were absent. Pallister-Hall and Smith-Lemli-Opitz syndromes were excluded based on the absence of typical features. Major discriminating features of pseudo-trisomy 13, hydroletharus and Meckel syndromes are presented in Table I as related to the present fetus.

Five pairs of affected sibs<sup>10,12-15</sup> and a family with three affected siblings<sup>16</sup> suggest an autosomal recessive inheritance for the condition. The fetus presented here provides further support for an autosomal recessive pattern of inheritance for the condition because of parental consanguinity. The first pregnancy had resulted in an abortion at the 10<sup>th</sup> gestational week, which may suggest the presence of congenital anomaly in that fetus also, but no postmortem examination or chromosomal analysis was performed. Although the mutated gene and the underlying pathogenetic mechanisms are yet to be defined, features strongly suggestive of trisomy 13 in patients with normal karyotypes should raise the suspicion of pseudo-trisomy 13 syndrome, particularly when parental consanguinity is present.

**Table I.** Features of Relevant Syndromes as Compared to the Present Fetus\*

Features	Present fetus	Pseudo-trisomy 13	Hydroletharus syndrome	Meckel syndrome
Parental consanguinity	+	+	+	+
Holoprosencephaly	+	+	+	+
Hydrocephaly	+	+	+	+
Postaxial polydactyly	+	+	+	+
Pulmonary segmentation defect	+	+	+	+
Central cleft lip	+	+	+	–
Single nostril	+	+	–	–
Hypotelorism	+	+	–	–
Hypertelorism	–	–	+	–
Micrognathia	–	+	+	–
Cleft palate	–	–	+	+
Posterior encephalocele	–	–	+	+
Polyhydramnios	–	–	+	–
“Key-hole shaped” foramen magnum	–	–	+	–
Cystic dysplastic kidneys	–	–	–	+

\* For the purpose of simplicity, only distinguishing features are included and the features are ordered to provide an easy overview of differential diagnosis.

## REFERENCES

1. Croen LA, Shaw GM, Lammer EJ. Holoprosencephaly: epidemiologic and clinical characteristics of a California population. *Am J Med Genet* 1996; 64: 465-472.
2. Greene MF, Benacerraf BR, Frigoletto FD. Reliable criteria for prenatal sonographic diagnosis of alobar holoprosencephaly. *Am J Obstet Gyn* 1987; 156: 687-689.
3. Muenke M, Cohen MC. Genetic approaches to understanding brain development: Holoprosencephaly as a model. *MRDD Research Reviews* 2000; 6: 15-21.
4. Croen LA, Shaw GM, Lammer EJ. Risk factors for cytogenetically normal holoprosencephaly in California: a population-based case-control study. *Am J Med Genet* 2000; 90: 320-325.
5. Nanni L, Croen LA, Lammer EJ, Muenke M. Holoprosencephaly: molecular study of a California population. *Am J Med Genet* 2000; 90: 315-319.
6. Cohen MM Jr, Gorlin RJ. Pseudo-trisomy 13 syndrome. *Am J Med Genet* 1991; 39: 332-335.
7. Young ID, Madders DJ. Unknown syndrome: holoprosencephaly, congenital heart defects and polydactyly. *J Med Genet* 1987; 24: 714-716.
8. Tolmie JL. Down syndrome and other autosomal trisomies. In: Rimoin DL, Connor JM, Pyeritz RE, Korf BR (eds). *Principles and Practice of Medical Genetics* (4<sup>th</sup> ed) Vol 1. China: Churchill Livingstone; 2002: 1129-1183.
9. Verloes A, Ayme S, Gambarelli D, et al. Holoprosencephaly-polydactyly ('pseudotrisomy 13') syndrome: a syndrome with features of hydrolethrus and Smith-Lemli-Opitz syndromes: a collaborative multicentre study. *J Med Genet* 1991; 28: 297-303.
10. Seller MJ, Chitty LS, Dunbar H. Pseudotrisomy 13 and autosomal recessive holoprosencephaly. *J Med Genet* 1993; 30: 970-971.
11. Lurie IW, Wulfsberg EA. "Holoprosencephaly-polydactyly" (pseudotrisomy 13) syndrome: expansion of the phenotypic spectrum. *Am J Med Genet* 1993; 47: 405-409.
12. Amor DJ, Woods CG. Pseudotrisomy 13 syndrome in siblings. *Clin Dysmorphol* 2000; 9: 115-118.
13. Atkin JF. A new syndrome with cyclopia and trisomy 13 features. *Am J Hum Genet* 1988; 43: A36.
14. Bachman H, Clark RD, Salahi W. Holoprosencephaly and polydactyly: a possible expression of the hydrolethrus syndrome. *J Med Genet* 1990; 27: 50-52.
15. Hennekam RC, van Noort G, de La Fuente AA. Familial holoprosencephaly, heart defects and polydactyly. *Am J Med Genet* 1991; 41: 258-262.
16. Schulz S, Gerloff C, Kalinski T, et al. Pseudotrisomy 13: clinical findings and genetic implications. *Fetal Diagn Ther* 2005; 20: 501-503.