

Pyoderma gangrenosum in a six-month-old boy

Güldane Koturoğlu¹, Fadıl Vardar¹, Ferda Özkınay¹, Zafer Kurugöl¹
Taner Akalın², Cihangir Özkınay¹

Departments of ¹Pediatrics and ²Pathology, Ege University Faculty of Medicine, Izmir, Turkey

SUMMARY: Koturoğlu G, Vardar F, Özkınay F, Kurugöl Z, Akalın T, Özkınay C. Pyoderma gangrenosum in a six-month-old boy. Turk J Pediatr 2006; 48: 159-161.

Pyoderma gangrenosum (PG) is an uncommon, chronic ulcerative condition of the skin that was first described in 1930. It can occur in any age group, but only 4% of the patients are infants or children. An underlying systemic disease is present in approximately 50% of the patients with PG. The most common associations include inflammatory bowel disease, arthritis, lymphoproliferative disorders and chronic recurrent multifocal osteomyelitis (CRMO). PG has been reported in association with CRMO in only a few children whose ages were between 18 months and 12 years.

We report a six-month-old boy who was diagnosed as CRMO based on his clinical examination and histological findings. This is the youngest case reported in the literature (under 12 months of age) with PG associated with CRMO.

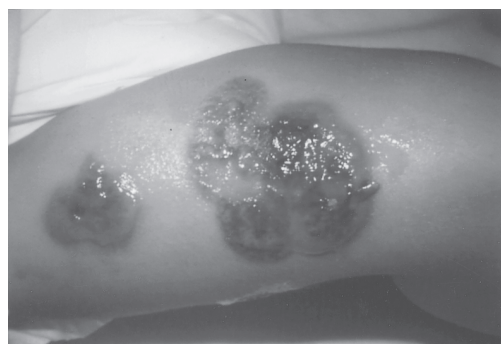Key words: chronic recurrent multifocal osteomyelitis, pyoderma gangrenosum, children.

Pyoderma gangrenosum (PG) is an uncommon, chronic ulcerative condition of the skin that was first described by Brunsting in 1930. It can occur in any age group, but only 4% of the patients are infants or children. An underlying systemic disease is present in approximately 50% of the patients with PG. The most common associated disorders are inflammatory bowel disease, arthritis, lymphoproliferative disorders and chronic recurrent multifocal osteomyelitis (CRMO)¹⁻⁴. CRMO is a clinicopathologic entity of unknown origin mainly affecting children and young adults⁵. Here we present the youngest case reported to date having PG associated with CRMO.

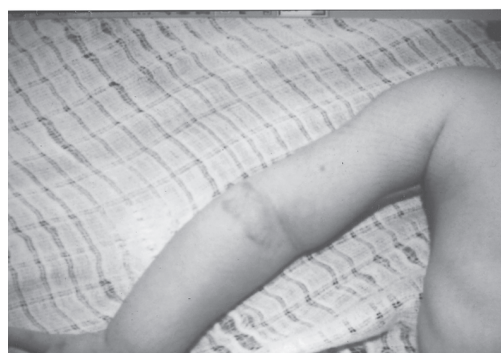Case Report

A six-month-old boy was admitted to Ege University Hospital with the complaints of fever, pain and swelling in the right hand, tenderness and skin lesions on the arms and legs for three months (Fig. 1). His past history was unremarkable. There was no consanguinity between parents.

On admission, physical examination revealed weight of 6150 g (3-10 percentile), length of 62 cm (10 percentile), heart rate 140/



(a)



(b)

Fig. 1. a) Violaceous, tender, superficially ulcerated plaque on the right arm. b) Skin lesions had diminished one month later.

minute, respiratory rate 48/minute and body temperature 38°C. Pseudovesicular lesions were observed on the right forearm and both legs. Increased temperature, erythema, and pain and tenderness around the lesions in those areas were also present. Otherwise he was normal. The initial skin lesions developed within a few weeks from small pseudovesicular lesions to large necrotic, hemorrhagic, suppurative, painful erosions with a diameter of 1-3 cm and irregular shape. A dermatologist was consulted regarding the patient, and biopsy and culture from the skin lesions and topical antibiotic treatment were suggested.

Laboratory evaluation revealed a hemoglobin level of 11 g/dl, white blood cell (WBC) count of 19,000/mm³, sedimentation rate of 90 mm/hr and C-reactive protein of 6.6 mg/dl. Peripheral blood smear showed 54% polymorphonuclear leukocyte (PNL) and 46% lymphocyte. Immunoglobulins, cellular immunity tests (CD19, CD3, CD4, CD8, NK and active T lymphocytes), Burst test, and complement level and adhesion molecules of CD11a, CD18 were normal. Human immunodeficiency virus serology was negative. Plain roentgenogram of the distal metaphysis part of the radius and ulna revealed osteolytic lesions consistent with osteomyelitis (Fig. 2).

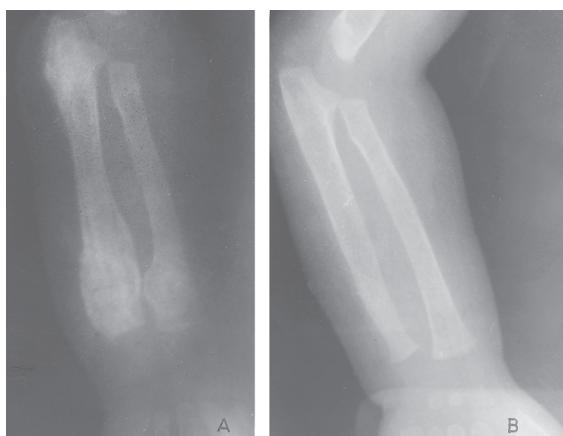

Fig. 2. a) Initial X-ray of right forearm shows osteolytic lesions consistent with osteomyelitis. b) Normal X-ray findings after treatment.

Intravenous teicoplanin, cefotaxime and a nonsteroid anti-inflammatory drug were administered for 15 days. Blood cultures and the cultures from skin and bone specimens taken before antibiotic treatment were negative for bacteria, mycobacteria and fungi. A dense

interstitial neutrophilic infiltration within the dermis and hyperplasia of epidermis were observed on histopathological examination of the specimen from the border of skin lesions (Fig. 3). On the 10th day of the treatment, new skin lesions at the site of skin biopsy and osteomyelitis in the right radius where the bone

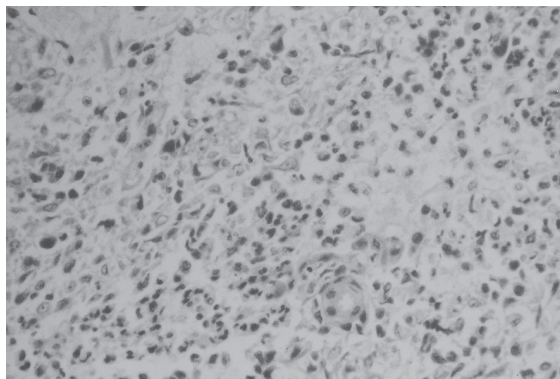


Fig. 3. Perivascular edema and neutrophilic infiltration in the dermis.

biopsy was performed were observed. On the bone scintigraphy, multifocal osteomyelitis of the left distal ulna, left distal humerus, ribs, upper thoracic and lower lumbar vertebrae and left distal tibia was detected (Fig. 4). Based on the histopathological findings of skin biopsy specimens combined with the clinical presentation of fever and leukocytosis, the diagnosis of PG was established. He was treated with oral prednisone (2 mg/kg/day). Topical steroid and topical antibiotic treatment were applied to skin lesions. Since minor trauma can

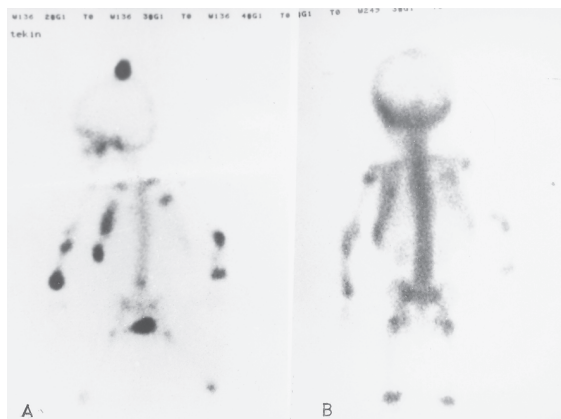


Fig. 4. a) Multifocal osteomyelitis of left distal ulna, left distal humerus, ribs, upper thoracic and lower lumbar vertebrae and left distal tibia was detected on the bone scintigraphy. b) Normal bone scintigraphy after treatment.

cause new skin lesions or exacerbate existing lesions of PG, the patient was protected against trauma and no surgical treatment was performed. Fever, pain and skin lesions started to improve. On the 10th day of the steroid therapy, varicella infection occurred and steroid treatment was interrupted. Two weeks later, steroid therapy was restarted with the same dosage. At the end of the first month of therapy, skin lesions had almost disappeared, and the pain and fever gradually diminished. The bone scintigraphy showed a progressive recovery within a month. After two months, steroid was stopped. Five months later skin lesions had totally resolved and there was no sign of osteomyelitis on the X-ray studies.

Discussion

Pyoderma gangrenosum is associated with systemic disorders in 50% of the cases. CRMO, which is a clinicopathologic entity of unknown origin, is an associated disorder and can be seen in rare cases with PG; it mainly affects children and young adults. To date, several cases between 18 months-12 years have been reported showing these two entities (PG, CRMO). Our case is the youngest case with these disorders. In PG, pain is the most common symptom associated with skin lesions surrounded with swelling and tenderness. Skin lesions usually begin as a small follicular papule or pustule that progressively enlarges. The surrounding skin is erythematous and indurated². In our case, biopsy specimens from the lesion demonstrated a dense perivascular and periappendageal infiltrate of neutrophils within the dermis. Other studies reporting similar histopathological findings have been described^{1,2}. Bone X-rays show multifocal osteomyelitis in the affected area which is resistant to antibiotic treatment. In the present case, osteomyelitis was first observed in the distal metaphysis of the radius and ulna. These lesions did not improve with antibiotic treatment and subsequent bone computerized tomography revealed multiple bone lesions in different areas. Cultures from different samples such as blood, urine, skin and biopsy specimens are sterile in cases with CRMO¹⁻³. In our case no bacterial growth was detected in blood, skin and the open bone biopsy specimen cultures.

It has been suggested to exclude primary and secondary immune deficiencies in cases showing similar findings². All tests investigating

primary and secondary immune deficiencies such as chronic granulomatous disease, leukocyte adhesion or complement system defect and human immunodeficiency virus serology were negative.

There is no specific therapy for CRMO, but nonsteroidal anti-inflammatory drugs, corticosteroids and interferon treatment have been used in some patients. Sundaram et al.⁶ reported a 10-year-old girl who developed a characteristic lesion of PG on her anterior leg 18 months after an open bone biopsy at the site. This patient also had ulcerative lesions, and corticosteroid therapy was effective. Nurre et al.² diagnosed sterile multifocal osteomyelitis in a three-year-old girl who had pain on the left hand and right leg. Perivascular edema and neutrophilic infiltration in the dermis were determined in skin biopsy histological examination.

Sweet syndrome and PG are in the group of neutrophilic dermatoses. Both are seen in rare cases together with CRMO. The lesions of the Sweet syndrome are characterized by non-ulcerative plaques and nodules that differ from the lesions observed in PG.

Pyoderma gangrenosum with CRMO was considered in our case based on clinical findings and the histopathologic examination of skin lesions, and steroid therapy was given for six weeks. The skin lesions and multifocal osteomyelitis responded to oral prednisone therapy. No recurrence was observed within a two-year period.

REFERENCES

1. Lori Schaen MD, Anita P, Sheth MD. Skin ulcers associated with a tender and swollen arm. *Arch Dermatology* 1998; 134: 9.
2. Nurre LD, Rabalais GP, Callen JP. Neutrophilic dermatosis-associated sterile chronic multifocal osteomyelitis in pediatric patients: case report and review. *Pediatr Dermatol* 1999; 16: 214-216.
3. Giedion A, Holthusen W, Masel LF, Vischer D. Subacute and chronic 'symmetrical' osteomyelitis. *Ann Radiol* 1972; 15: 324-342.
4. Jahangier ZN, Jacobs JW, Bijlsma JW. SAPHO syndrome: common denominator for various bone and skin diseases. *Ned Tijdschr Geneesk* 1997; 141: 764-769.
5. Omid CJ, Siegfried EC. Chronic recurrent multifocal osteomyelitis preceding pyoderma gangrenosum and occult ulcerative colitis in a pediatric patient. *Pediatr Dermatol* 1998; 15: 435-438.
6. Sundaram M, McDonald D. Chronic recurrent multifocal osteomyelitis: an evolving clinical and radiologic spectrum. *Skeletal Radiol* 1996; 25: 333-336.