

A Burkitt's lymphoma case with eyelid, renal and pulmonary involvement

Yavuz Köksal¹, İsmail Reisli¹, Canan Uçar¹, Mustafa Avunduk²

Saim Açıkgözoğlu³, Ümran Çalışkan¹

Departments of ¹Pediatrics, ²Pathology, and ³Radiology, Selçuk University Meram Faculty of Medicine, Konya, Turkey

SUMMARY: Köksal Y, Reisli İ, Uçar C, Avunduk M, Açıkgözoğlu S, Çalışkan Ü. A Burkitt's lymphoma case with eyelid, renal and pulmonary involvement. Turk J Pediatr 2006; 48: 181-184.

An eight-year-old boy was admitted with a three-week history of painless masses on the left upper eyelid, in front of the left ear and on the left side of his jaw. On examination, there was a 3x2 cm tumor on the left upper eyelid, and lymphadenopathies in front of the tragus and in the left submandibular area were observed in the absence of hepatosplenomegaly. Complete blood count, peripheral smear and bone marrow aspiration were normal. After the left submandibular lymphadenopathy was removed, he was diagnosed with Burkitt's lymphoma by pathological examinations. Thorax and abdomen computed tomography showed pulmonary and renal involvement. On the seventh day of treatment, eyelid involvement disappeared. After induction therapy, no renal or pulmonary lesions were observed. An unusual clinical presentation of Burkitt's lymphoma with eyelid and pulmonary involvement is reported.

Key words: Burkitt's lymphoma, eyelid, pulmonary, renal, childhood.

Burkitt's lymphoma is an undifferentiated tumor that was first defined in East Africa in 1958¹. The African type frequently presents with jaw involvement, but in the American type intra-abdominal location is more common^{2,3}. While liver, spleen, bone marrow and central nervous system involvement are common, cutaneous and subcutaneous tissue, the orbits, thyroid, bones, kidneys, epidural space, breasts and gonads are rarely involved^{2,3}. We present a case of Burkitt's lymphoma with eyelid, pulmonary and kidney involvement.

Case Report

An eight-year-old boy was admitted to our clinic with a three-week history of painless masses on the left upper eyelid, in front of the left ear and on the left side of his jaw. His examination revealed a 3x2 cm tumor on the left upper eyelid, a 2x2 cm lymphadenopathy in front of the tragus and a 3x2 cm lymphadenopathy in the left submandibular area (Fig. 1a).

Hepatosplenomegaly was not observed. The peripheral blood count showed a hemoglobin level of 13.2 g/dl, hematocrit value of 38.9%,

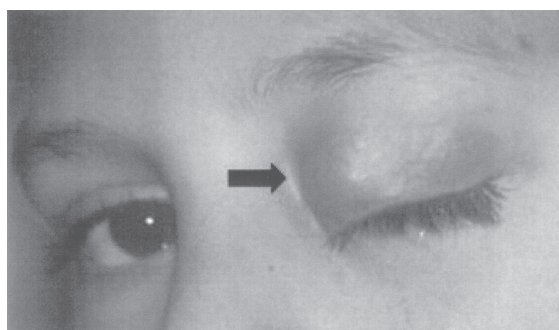


Fig. 1. a) Appearance of the patient before treatment.

platelet count of 303,000/mm³ and white blood cell count of 6,400/mm³ with normal differential. No atypical cells were seen in his peripheral blood smear. The erythrocyte sedimentation rate was 21 mm/h and the serum biochemistries were normal except for a slightly elevated lactate dehydrogenase level (894 U/L). Bone marrow aspiration and biopsy were normal. The serology of Epstein-Barr virus (EBV) and cytomegalovirus (CMV) suggested a past infection, and the anti-human immunodeficiency virus (HIV) antibody was

negative. Cranial and neck computed tomography revealed an irregular-bordered soft tissue lesion having a hypodense part that formed a thickness on the left upper eyelid. There were multiple lymphadenopathies established in the left preauricular and submandibular areas and cervical chain. The left submandibular lymphadenopathy was excised and its pathological examination showed the tumor cells and their nuclei to be fairly uniform, giving a monotonous appearance. "Starry sky" patterns were observed. On immunohistochemical studies, CD20 and CD79a tests were strongly positive and Ki67 antigen was determined in more than 90% of neoplastic cells, but CD30 was negative. The patient was diagnosed with Burkitt's lymphoma based on all these findings. The bone marrow examination, bone marrow biopsy and cytology of the cerebrospinal fluid were normal. Chest computed tomography showed multiple, small, irregular-shaped, non-homogeneous nodules in the subpleural spaces of the right lobe (Fig. 2). In the abdominal computed tomography, both kidneys were larger and had soft tissue lesions that appeared to be less opaque than in the parenchyma. With the diagnosis of stage III non-Hodgkin's lymphoma, the patient was treated with Murphy's non-Hodgkin's lymphoma schema for stage III undifferentiated lymphoma⁴.

The mass on the left upper eyelid of the child disappeared on the seventh day of treatment (Fig. 1b). After induction therapy, no pulmonary or kidney lesions were observed. He currently has been off treatment for 30 months and is free of the primary disease.

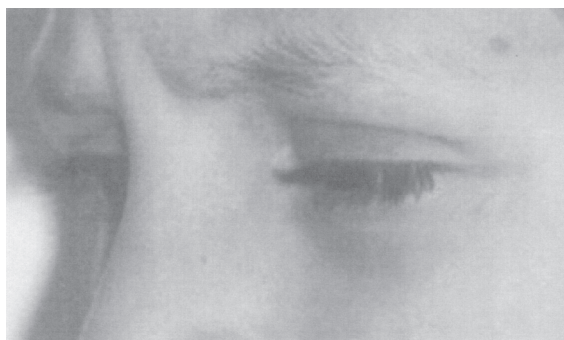

Fig. 1. b) Appearance on the seventh day of treatment.

Discussion

Childhood non-Hodgkin's lymphomas are diffuse and high-grade lymphomas differentiated into three main groups: Burkitt's lymphoma,

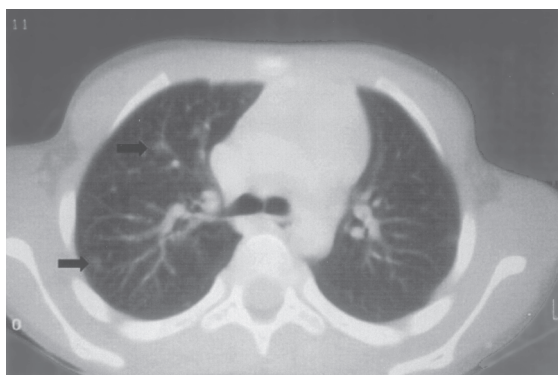


Fig. 2. Chest computed tomography showed multiple, irregular-shaped, non-homogeneous small nodules settled in the subpleural spaces of the right lobe.

lymphoblastic lymphomas and large cell anaplastic lymphomas^{2,3}. Burkitt's lymphoma constitutes 34% of non-Hodgkin's lymphomas⁵. While the first part affected is the jaw in the African type, the American type usually expresses itself by abdominal involvement, especially the ileocecal segment of the intestine^{2,3,5}. Liver, spleen, bone marrow and central nervous system involvement are common, unlike involvement of cutaneous and subcutaneous tissue, the orbits, thyroid, bones, kidneys, epidural space, breasts and gonads^{2,3}.

Kodsi and colleagues⁶ reported that primary orbital lymphoma occurred in five patients, but leukemic involvement of the orbits was found in none. Shields and colleagues⁷ investigated 117 patients with conjunctival lymphoid tumors. They found only three cases with eyelid involvement. In another study, the incidence of eyelid involvement with non-Hodgkin's lymphoma was 8%⁸. Templeton and colleagues⁹ reported that of 312 patients with orbit tumors, only of three of them had Burkitt's lymphoma on their eyelids. Primary eyelid involvement is rarely seen in Burkitt's lymphoma. In the literature, there are two case reports about eyelid involvement: in a 15-year-old boy and in a 26-month-old boy^{10,11}. Burkitt's lymphoma associated with eyelid and bone marrow involvement was observed in a 15-year-old Turkish boy¹⁰. Another case concerned a 26-month-old boy admitted to hospital with the complaint of oral thrush and painless swelling of the right upper eyelid. An incisional biopsy of the orbital mass was performed and the histopathologic examination revealed a high-grade lymphoid neoplasm that was positive for B cell markers¹¹.

Lymphoblastic lymphoma most commonly presents as a mediastinal tumor, often with associated pleural effusion. Pleural effusion may be produced by direct pleural involvement and/or result from the compression of lymphatics by the mediastinal mass. The frequency of involvement of the mediastinum is 1-12% in Burkitt's lymphoma³. Pleural effusion usually exists but the pulmonary parenchyma is rarely involved. In the literature, it is reported that two of 12 Burkitt's lymphoma patients had pulmonary nodules¹². In our case, we noted pulmonary parenchyma involvement on computed tomography.

Involvement of the kidneys is frequent. Buyukpamukcu and colleagues¹³ reported that among 1,365 children followed with non-Hodgkin's lymphoma, 7.6% had unilateral and/or bilateral renal involvement at initial presentation. Such involvement is almost invariably secondary, and primary renal non-Hodgkin's lymphoma is extremely rare. The most common appearance of renal lymphoma in children on ultrasound or computed tomography is bilateral renal masses, with solitary masses or diffuse renal enlargement¹⁴.

In Turkish children, the incidence of orbit involvement at initial presentation of Burkitt's lymphoma was reported as 20.8%, but that of eyelid involvement is unknown¹⁵. Renal involvement in Burkitt's lymphoma had been reported to be 6.3% in Turkish children¹⁶. No involvement of the lungs in cases of Burkitt's lymphoma has been reported^{15,16}. Pleural effusion was present in 11.1% of patients with Burkitt's lymphoma. However, no pulmonary parenchyma was determined^{15,16}.

Our patient presented with eyelid and cervical masses. We performed an incisional biopsy of the cervical mass and diagnosed Burkitt's lymphoma. Abdomen ultrasonography and computed tomography revealed bilateral enlarged kidneys with increased echogenicity. Chest computed tomography showed multiple, small, irregular-shaped, non-homogeneous nodules in the subpleural spaces of the right lobe. Interestingly, although he had eyelid, lymph node, kidney and lung involvement, we did not determine bone marrow involvement by bone marrow aspiration or biopsy. We administered systemic chemotherapy. On the seventh day of treatment, the eyelid and cervical masses disappeared.

In conclusion, Burkitt's lymphoma is a high-grade, aggressive subgroup of non-Hodgkin's lymphoma. Most organ or system involvement, such as of the liver, spleen, bone marrow and central nervous system, is common, but involvement of cutaneous and subcutaneous tissue, the orbits, thyroid, bones, kidneys, epidural space, lungs, breasts and gonads is rare. We report a case of Burkitt's lymphoma with eyelid, lung and renal involvement. We treated this case successfully with an intensive and multi-drug chemotherapy regimen. In particular, involvement of the eyelids in cases of lymphoma must be considered during the identification of rhabdomyosarcoma, eosinophilic granuloma, allergic fungal sinusitis and orbita ocular granulocytic sarcoma, which present with orbital masses.

REFERENCES

1. Burkitt D. A sarcoma involving the jaws in African children. *Br J Surg* 1958; 46: 218-223.
2. Patte C. Non-Hodgkin's lymphoma. In: Pinkerton CR, Plowman PN (eds). *Paediatric Oncology* (2nd ed). London: Chapman. Hall Medical; 1997: 278-296.
3. Magrath IT. Malignant non-Hodgkin's lymphomas in children. In: Pizzo PA, Poplack DG (eds). *Principles and Practice of Pediatric Oncology* (4th ed). Philadelphia: Lippincott Williams, Wilkins; 2002: 661-705.
4. Murphy SB, Bowmann WP, Abromotich M, et al. Results of treatment of advanced stage Burkitt's lymphoma and B-cell (Sig+) acute lymphoblastic leukemia with high dose fractionated cyclophosphamide and coordinated high dose methotrexate and cytarabine. *J Clin Oncol* 1986; 4: 1732-1739.
5. National Cancer Institute sponsored study of classification of non-Hodgkin's lymphoma: summary and description of a working formulation for clinical usage. *Cancer* 1982; 49: 2112-2135.
6. Kodsi SR, Shetlar DJ, Campbell RJ, Garrity JA, Bartley GB. A review of 340 orbital tumors in children during a 60-year period. *Am J Ophthalmol* 1994; 117: 177-182.
7. Shields CL, Shields JA, Carvalho C, Rundle P, Smith AF. Conjunctival lymphoid tumors: clinical analysis of 117 cases and relationship to systemic lymphoma. *Ophthalmology* 2001; 108: 979-984.
8. Knowles DM, Jakobiec FA, McNally L, Burke JS. Lymphoid hyperplasia and malignant lymphoma occurring in the ocular adnexa (orbit, conjunctiva, and eyelid): a prospective multiparametric analysis of 108 cases during 1977 to 1987. *Hum Pathol* 1990; 21: 959-973.
9. Templeton AC. Tumors of the eye and adnexa in Africans of Uganda. *Cancer* 1967; 20: 1689-1698.
10. Cehreli C, Tosun N. Burkitt's lymphoma cell leukemia in a Turkish boy. *Cancer* 1975; 36: 1444-1449.

11. Edalstein C, Shields J, Shileds CL, et al. Non-African Burkitt lymphoma presenting with oral thrush and an orbital mass in a child. *Am J Ophthalmol* 1997; 124: 859-861.
12. Alford BA, Cocoa PF, L'Heureux PR. Roentgenographic features of American Burkitt's lymphoma. *Radiology* 1977; 124: 763-770.
13. Buyukpamukcu M, Varan A, Aydin B, et al. Renal involvement of non-Hodgkin's lymphoma and its prognostic effect in childhood. *Nephron Clin Pract* 2005; 100: 86-91.
14. Chepuri NB, Strouse PJ, Yanik GA. CT of renal lymphoma in children. *AJR* 2003; 180: 429-431.
15. Cavdar AO, Gozdasoglu S, Yavuz G, et al. Burkitt's lymphoma between African and American types in Turkish children: clinical, viral (EBV), and molecular studies. *Med Pediatr Oncol* 1993; 21: 36-42.
16. Ertem U, Duru F, Pamir A, et al. Burkitt's lymphoma in 63 children diagnosed over a 10 year period. *Pediatr Hematol Oncol* 1996; 13: 123-134.