

Hypomelanosis of Ito with trisomy 13 mosaicism [46, XY, der (13;13) (q10;q10), +13/46,XY]

Cengiz Yakıncı¹, Nurettin Onur Kutlu¹, M. Nail Alp², Mustafa Şenol³

Yaşar Durmaz¹, Turgay Budak³

Departments of ¹Pediatrics, and ²Medical Biology, Dicle University Faculty of Medicine, Diyarbakır, and ³Department of Dermatology, İnönü University Turgut Özal Medical Center, Malatya, Turkey

SUMMARY: Yakıncı C, Kutlu NO, Alp MN, Şenol M, Durmaz Y, Budak T. Hypomelanosis of Ito with trisomy 13 mosaicism [46, XY, der (13;13) (q10;q10), +13/46, XY]. Turk J Pediatr 2002, 44: 152-155.

The term hypomelanosis of Ito (HI) has been used as a diagnosis for individuals with swirly hypopigmentation or depigmentation distributed along the lines of Blaschko. HI should be appropriately evaluated for a possible association with chromosomal or genetic mosaicism or chimerism. We report a six-month-old severely motor and mental retarded boy with these typical cutaneous lesions associated with extracutaneous features, including facial dysmorphism, polydactyly, and inguinal hernia. The cytogenetic examination of lymphocytes demonstrated a mosaicism of 46, XY, der (13;13) (q10;q10), +13/46, XY. This is the first case reported in the literature showing an association between phylloid pigmentary pattern of hypomelanosis of Ito and trisomy 13 mosaicism.

Key words: hypomelanosis of Ito, trisomy 13 mosaicism, phylloid cutaneous pattern, West's syndrome.

A current debate is that certain genetic mechanisms leading to mosaicism are responsible for certain cutaneous patterns. Recent reports have shown that cutaneous symptoms of most of the congenital neurocutaneous syndromes were associated with an underlying chromosome mosaicism or chimerism¹.

Hypopigmentation along the lines of Blaschko is currently thought to be caused by mosaicism that is localized or generalized depending on the stage of fetal development at which the genetic mutation occurs². The constancy of the Blaschko's lines in different dermatomes indicates a normal function rather than a pathologic effect. These lines reflect the streams of growth of embryonic tissues¹. Chromosomal mosaicism and random distribution of two clones of cells with different pigment potentials with the capability of becoming melanoblasts are responsible in the pathogenesis³.

In respect of pigmentary disturbance, mosaicism may cause different cutaneous patterns such as classic (lines of Blaschko), checkerboard, phylloid, or patchy patterns without midline

separation². The lines of Blaschko are well known to physicians but other patterns such as the phylloid type have so far been entirely ignored.

We present a case with phylloid cutaneous pattern and some extracutaneous manifestations accompanied by Patau's syndrome as well as chromosome 13 mosaicism.

Case Report

A six-month-old severely retarded Turkish boy with typical hypopigmented skin lesions along Blaschko's lines on his trunk noted at the age of one week (without previous history of inflammation, vesiculation, suppuration, or desquamation) was admitted for the evaluation of bilateral polydactyly and left inguinal hernia. His father was 48 and mother was 32 years old. He had two brothers and two sisters, all healthy. On physical examination, his length was 64.5 cm (25th centile) and his weight was 7.2 kg (50th centile), and his occipitofrontal head circumference was 40.1 cm (below 3rd centile). The hypopigmented lesions were bilateral, midline separated, asymmetric leaf-shaped, and

variable in size, found on the trunk and tending to run parallel to each other with spared extremities (Fig. 1a, 1b). He also had microcephaly, psychomotor retardation (two months according to Denver II Developmental Screening Test), coarse facial appearance, umbilical hernia, cryptorchidism, and seizure disorder which manifested as neck and whole body flexion. Routine laboratory and cranial computerized tomography findings were normal. No obvious cardiac, renal, skeletal, or other internal abnormalities were detected. For the chromosomal analysis, peripheral blood culture method⁴ was used and slides were stained by trypsin G-banding technique. Peripheral blood of the patient and of his parents was taken and cultured.

The patient was found as mosaic. Some metaphases of the patient were found as normal and others were found trisomic for the long arm of chromosome 13. The breakage and reunion occurred at the band 13q10. The derivative chromosome replaced the long arm of two

chromosomes 13. There was, however, one normal chromosome 13 as well. So, the karyotype of the patient was designated as: mos 46, XY, +13, der (13;13) (q10;q10) [27]/46, XY [23] (Fig. 2). The derivative chromosome was identified in 27 of 50 metaphases and 23 metaphases were found to have normal karyotype. Thus, the frequency of the trisomic cells was approximately 50%. Chromosomal analyses of parents were carried out and their karyotypes were found to be normal. Therefore, Robertsonian translocation between the chromosomes 13 of the cases was considered *de novo*.

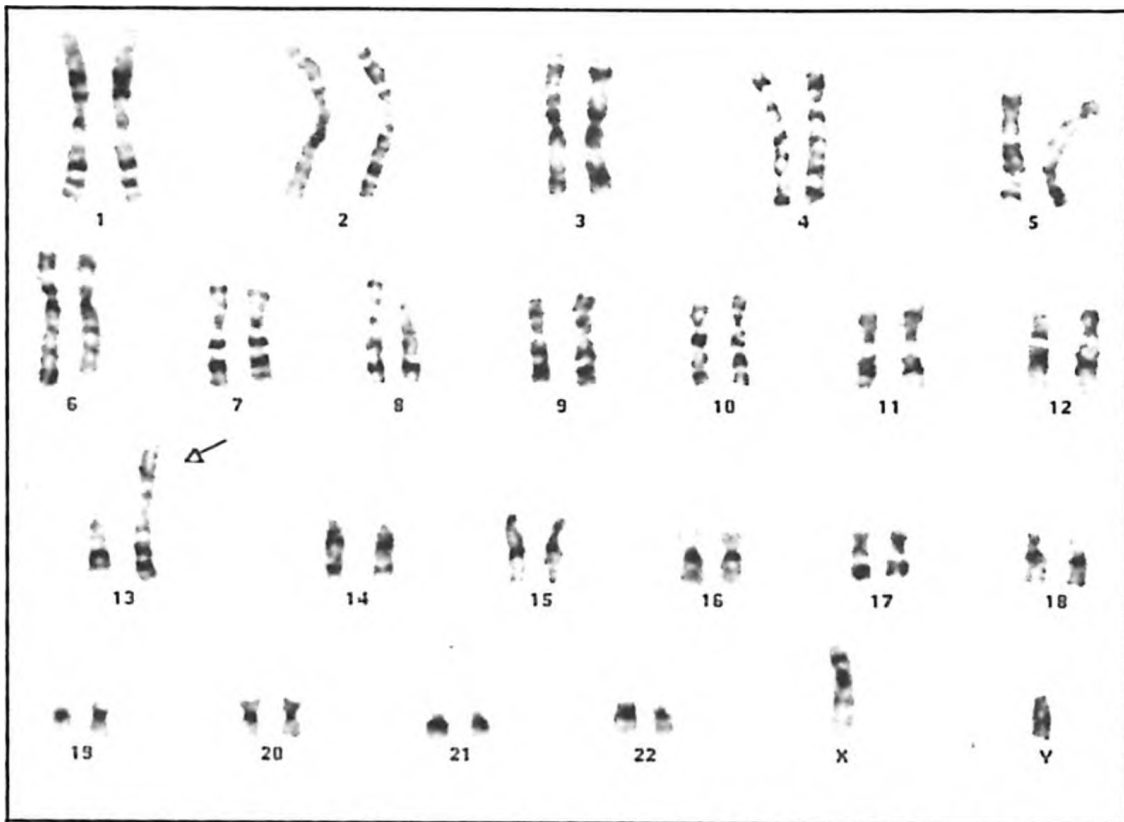
Electroencephalogram demonstrated hypsarrhythmia. The characteristic clinical and electroencephalographic features favored the diagnosis of West's syndrome. The seizures responded to adrenocorticotrophic hormone and valproate treatment. On his follow-up, he died from pneumonia at eight months of age.

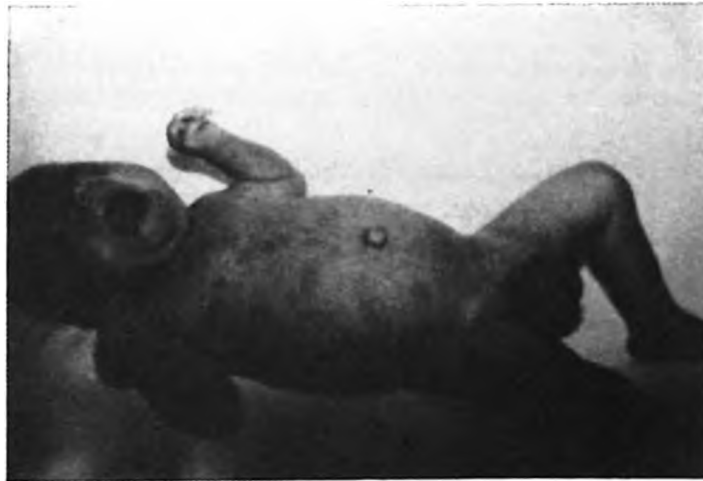

Fig. 1a. Hypopigmented leaf-shaped patches with midline separation on the front of the patient (printed with written permission from the patient's parent).

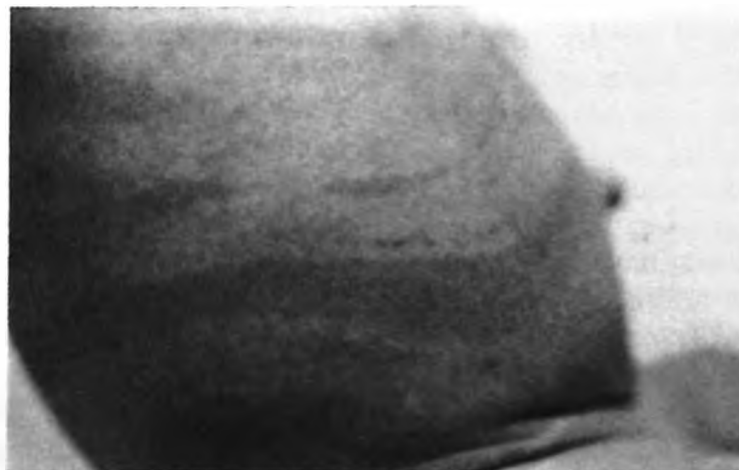

Fig. 1b. Hypopigmented leaf-shaped patches on the lateral aspect of the case.



Case: 1997-445 Slide: COCUK Cell: 1 Patient: F.T.

Fig. 2. Karyotype of the case: trisomy for the long arm of chromosome 13 mosaicism [mos 46, XY, +13, der (13;13) (q10;q10) [27]/46, XY [23]].

Discussion

Hypomelanosis of Ito (HI) is one of the well known syndromes in which chromosomal instability may be a component⁵. A number of studies have demonstrated miscellaneous chromosomal abnormalities in some but not all affected individuals⁶; however, there is still no consistent chromosomal finding, and a monogenic cause for HI seems so far unlikely⁷. Therefore, it has been suggested that HI is not a single condition but rather a nonspecific manifestation (i.e., phenotype) of chromosomal mosaicism.

Karyotyping of peripheral blood, and, if this is normal, of skin fibroblasts or better keratinocytes or melanocytes obtained from biopsies taken from affected and unaffected areas, should be performed in affected individuals to support the diagnosis⁶. Chromosomal alterations, however, have been documented in only half of the affected patients in the literature and can be currently classified into two groups: 1) various mosaicism for almost any autosome or sex chromosomes, including tetrasomy 12p, trisomy 18, diploidy/triploidy 45, X/46, X r(X) or 45, X/46, X, +mar and 46, XX/46, XY chimerism. The only consistent feature of this group is that at least

two chromosomally different cell lines are present; 2) non-mosaic balanced X; autosome translocations with breakpoints in the juxtacentromeric region of the X chromosome at Xp11 found in a group of girls with skin pigmentary abnormalities in Blaschko's lines and multiple developmental defects including severe mental retardation⁶.

What is still unclear in the pathogenesis of HI, however, is how such a variety of different karyotypes should result in a similar linear dyspigmentation, since the control of pigmentation is certainly complex and polygenic, but pigment genes are not likely to be at all of these loci⁸. Mosaicism may produce some kinds of cutaneous pigmentary patterns such as classic pattern through lines of Blaschko, checkerboard pattern, phylloid (leaf-shaped) pattern, and a patchy pattern². So far, phylloid pattern has been described in five patients of whom two had trisomy 13 mosaicism⁹ and one had pure trisomy 13¹⁰. In this patient the pigmentary disturbance did not follow the Blaschko's lines. This observation fits with type 3 (phylloid pattern) of Happle⁹ who proposed classification of pigmentary patterns associated with mosaicism.

Associated systemic manifestations seen in HI are primarily neurological, musculoskeletal, and ocular, including mental retardation, seizures, macrocephaly or microcephaly, hemihypertrophy, kyphoscoliosis, hypertelorism, strabismus, and myopia. Other associated disorders occur inconsistently and include coarse facial features, syndactyly, clinodactyly, short stature, genital anomalies, inguinal hernia, congenital heart disease, and abnormalities of the teeth and feet¹¹. In a series of 72 children with HI, Pascual-Castroviejo et al.¹² reported 57% with mental retardation, 10% with autistic behavior, 21% borderline and only 22% with normal mental status (IQ > 85). Seizures in various types were present in 49% of cases consisting of infantile spasms in six cases (8%)¹². The fact that there were no specific EEG or evoked potential findings for HI seems to be consistent with the pathogenetically heterogeneous nature of this disorder¹³.

The differential diagnosis of HI therefore includes disorders of hypopigmentation that follow Blaschko's lines; the hypopigmented fourth stage of incontinentia pigmenti, Goltz syndrome, and the generalized forms of nevus depigmentosus¹⁴. Incontinentia pigmenti, like HI, is associated with ectodermal, neurologic and musculoskeletal abnormalities, and it has a hypopigmented fourth stage in approximately 14% of patients. These hypopigmented lesions usually appear on extremities, and are usually preceded by vesicobullous, verrucous, and hyperpigmented stages¹⁴⁻¹⁶. In our case, characteristic macules had been present since the age of one week, and there was no history of preceding vesiculobullous, verrucous, or hyperpigmented stages.

The features accompanying our case were West's syndrome, microcephaly, coarse facial features, polydactyly, cryptorchidism, and inguinal hernia. All of these clinical features are also the same clinical characteristics of trisomy 13 syndrome. Moreover, this finding supported the hypothesis that underlying chromosomal malformations, at least in some cases, play a definitive role in determination of the clinical appearance of HI, either with cutaneous or extracutaneous malformations.

We conclude that specific genetic anomalies, when present as a mosaic, can produce the same type of cutaneous pattern. We present a typical case of incontinentia pigmenti achromians with trisomy 13 mosaicism.

REFERENCES

1. Horn D, Rommeck M, Sommer D, Korner H. Phylloid pigmentary pattern with mosaic trisomy 13. *Pediatr Dermatol* 1997; 14: 278-280.
2. Donnai D, Read AP, Mckeown C, Andrews T. Hypomelanosis of Ito. a manifestation of mosaicism and chimerism. *J Med Genet* 1988; 25: 809-818.
3. Thomas IT, Frias JL, Cantu ES, Lafer CZ, Flannery DB, Graham JG. Association of pigmentary anomalies with chromosomal and genetic mosaicism and chimerism. *Am J Hum Genet* 1989; 45: 193-205.
4. Moorhead PS, Nowel PC, Mellman WJ, Battips DM, Hungerford DA. Chromosome preparations of leukocytes cultured from human peripheral blood. *Exptl Cell Res* 1960; 20: 613-616.
5. Ruiz-Moldonado R, Toussaint S, Tamayo L, Laterza A, del Castillo V. Hypomelanosis of Ito: diagnostic criteria and report of 41 cases. *Pediatr Dermatol* 1992; 9: 1-10.
6. Ruggieri M, Pavon L. Hypomelanosis of Ito: clinical syndrome or just phenotype? *J Child Neurol* 2000; 15: 635-644.
7. Moss C, Savin J. Skin development and its disorders. In: Moss C, Savin J (eds). *Dermatology and the New Genetics*. Oxford: Blackwell Science; 1995: 1-35.
8. Pellegrino JE, Schnur RE, Kline R. Mosaic loss of 15q11q13 in a patient with hypomelanosis of Ito: is there a role for the P gene? *Hum Genet* 1995; 96: 485-489.
9. Happle R. Mosaicism in human skin. Understanding the patterns and mechanisms. *Arch Dermatol* 1993; 129: 1460-1470.
10. Pillay T, Winship WS, Ramdial PK. Pigmentary abnormalities in trisomy of chromosome 13. *Clin Dysmorphol* 1998; 7: 191-194.
11. Gordon N. Hypomelanosis of Ito (incontinentia pigmenti achromians). *Dev Med Child Neurol* 1994; 36: 271-274.
12. Pascual-Castroviejo I, Roch C, Martinez-Bermejo A, et al. Hypomelanosis of Ito. A study of 76 infantile cases. *Brain Dev* 1998; 20: 36-43.
13. Ogino T, Hata H, Minakuchi E, Iyoda K, Narahara K, Ohtahara S. Neurophysiologic dysfunction in hypomelanosis of Ito. EEG and evoked potential studies. *Brain Dev* 1994; 16: 407-412.
14. Berg Bo. *Unusual Neurocutaneous Syndromes*. Neurologic Clinics Vol. 3. Philadelphia: WB Saunders Co; 1985: 167-169.
15. Balci S, Kara A, Gököz A, Köse G, Aktaş D. A Turkish case of incontinentia pigmenti with sister chromatid exchange. *Turk J Dermatopathol* 1997; 3-4: 89-93.
16. Tuncer M, Balci S, Tinaztepe B, Tuncer S. Incontinentia pigmenti (Bloch-Sulzberger sendromu) (Histolojik ve immunohistolojik çalışması yapılmış iki vaka nedeni ile). *Çocuk Sağlığı ve Hastalıkları Dergisi* 1984; 27: 93-102.