

# Utility of dobutamine stress echocardiography in Kawasaki disease: a case report and review of the literature

Barış Ökçün, Hakan Özhan, Türker Baran, Levent Saltık, Haşim Mutlu  
Sinan Üner, M. Serdar Küçükoglu

*Institute of Cardiology, İstanbul University, İstanbul, Turkey*

**SUMMARY:** Ökçün B, Özhan H, Baran T, Saltık L, Mutlu H, Üner S, Küçükoglu MS. Utility of dobutamine stress echocardiography in Kawasaki disease: a case report and review of the literature. *Turk J Pediatr* 2001; 251-253.

Dobutamine stress echocardiography (DSE) has become widely accepted in the evaluation of adult patients with coronary heart disease. There are new challenges about the use of DSE in the pediatric age group to document ischemia. DSE can demonstrate ischemia noninvasively in Kawasaki disease (KD) patients who are candidates for coronary angiography. We wanted to assess the feasibility and the physiologic responses of DSE in a KD patient with coronary aneurysm. The patient had no ischemia in DSE, which was confirmed by coronary angiography showing no stenosis. The literature about DSE use in KD is reviewed.

**Key words:** *dobutamine stress echocardiography, Kawasaki disease.*

Dobutamine stress echocardiography (DSE) has become a diagnostic tool for the evaluation of coronary artery disease and the detection of myocardial viability. In the diagnosis of significant coronary artery disease, it provides similar accuracy to exercise stress thallium-201 myocardial perfusion scintigraphy. Dobutamine stress echocardiography is also a promising modality for predicting the recovery of hibernating myocardium from contractile dysfunction after coronary angioplasty or bypass surgery. Recently, quite a number of studies have been done with DSE in the pediatric population<sup>1-3</sup>. Kawasaki disease (KD), heart transplant patients and children taking anthracycline therapy were especially investigated<sup>1</sup>. We report a case of a six-month-old Kawasaki disease patient complicated with coronary artery aneurysm. DSE was performed the first such pediatric case in our institute, to evaluate ischemia presence and the result was compared with coronary artery angiography, the gold standard for detecting stenotic lesions causing ischemia.

## Case Report

A six-month-old male patient was admitted to a university hospital due to resistant fever and was diagnosed as Kawasaki disease. He was

referred to our clinic for transthoracic echocardiography (TTE) to reveal any coronary artery aneurysms. There were aneurysms of 12×16 mm and 6×15 mm in diameter in his left and right coronary artery, respectively. TTE was normal otherwise.

In order to determine if the underlying lesions caused any ischemia, DSE was performed. Prior to dobutamine infusion, rest electrocardiogram, parasternal short- and long-axis, and apical 4-2 chamber views were recorded. There were no left ventricular or valve function abnormalities. Ejection fraction was 70%. Dobutamine was started at a dose of 5 µg/kg/min. The dose was increased 5 µg/kg/min every three minutes, until the maximum dose of 40 µg/kg/min was reached. Heart rate and blood pressure were recorded at each step, and electrocardiograms were recorded before and at the end of the perfusion. During DSE no wall motion abnormality was seen. The test was negative for ischemia (Figs. 1a and 1b). Coronary angiography showed aneurysmal dilatations without any stenosis, in both right and left coronaries (Figs. 2a and 2b).

## Discussion

Kawasaki disease has a risk of coronary artery inflammation and aneurysm formation in 5-20%

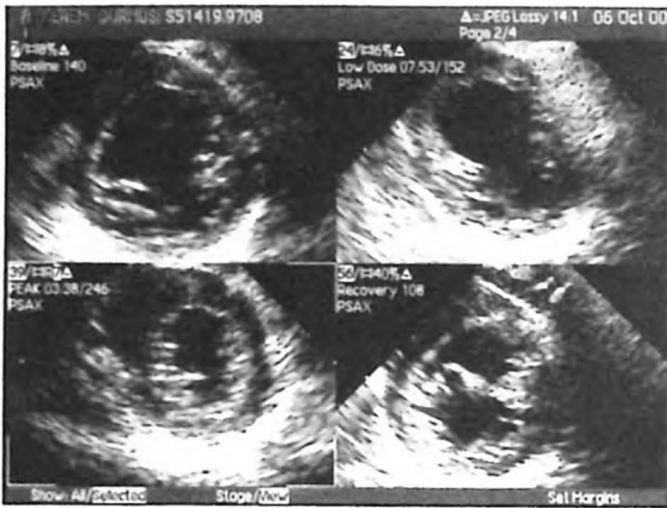


Fig. 1a. Dobutamine stress echocardiography parasternal short-axis views at the beginning of study, at low dose ( $5 \mu\text{g}/\text{kg}/\text{min}$ ) dobutamine infusion, at maximum dose ( $40 \mu\text{g}/\text{kg}/\text{min}$ ) infusion and at the end of recovery period. No wall motion abnormality can be seen.

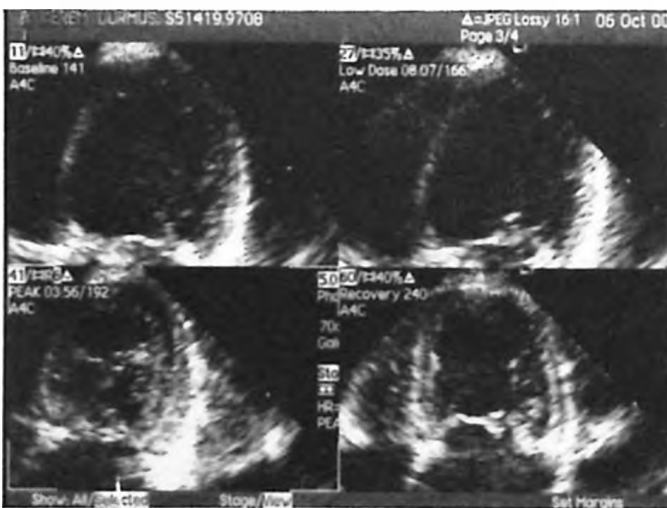


Fig. 1b. Dobutamine stress echocardiography apical four-chamber views at the beginning of study, at low dose ( $5 \mu\text{g}/\text{kg}/\text{min}$ ) dobutamine infusion, at maximum dose ( $40 \mu\text{g}/\text{kg}/\text{min}$ ) infusion and at the end of recovery period. No wall motion abnormality can be seen.

of patients. The most common cause of death is due to cardiac complications. Children under one year of age appear to be at particularly high risk for development of coronary abnormalities. In a study from Japan, from January 1973 through December 1992, a total of 302 patients (183 males, 119 females) with KD underwent coronary angiography. Coronary abnormalities were confirmed in 71 (23.5%) of 302 cases. Serial angiographic evaluation of 42 cases revealed different progressions in coronary abnormalities<sup>4</sup>. The sensitivity of two-dimensional echocardiography is 100% in

detecting aneurysms in the proximal portions of both the right and left coronary arteries, and is useful in selecting patients for invasive investigation with selective coronary arteriography<sup>5</sup>. In a recent study of 594 patients with KD, 24.6% were diagnosed as having coronary aneurysms, and during follow-up, ischemic heart disease developed in 4.7% and myocardial infarction in 1.9%. Death occurred in 0.8%. The 448 patients with normal findings at the first angiogram subsequently never developed any abnormal cardiac findings<sup>6</sup>. It is important to treat the localized stenosis in preventing myocardial infarction in the chronic phase of KD. Since coronary angiography is an invasive

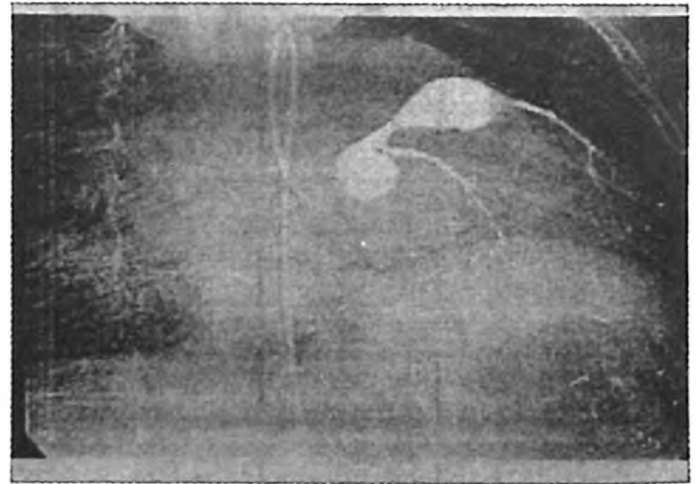

Fig. 2a. Coronary artery angiography demonstrating aneurysm formation in left anterior descending artery without any stenotic lesion.

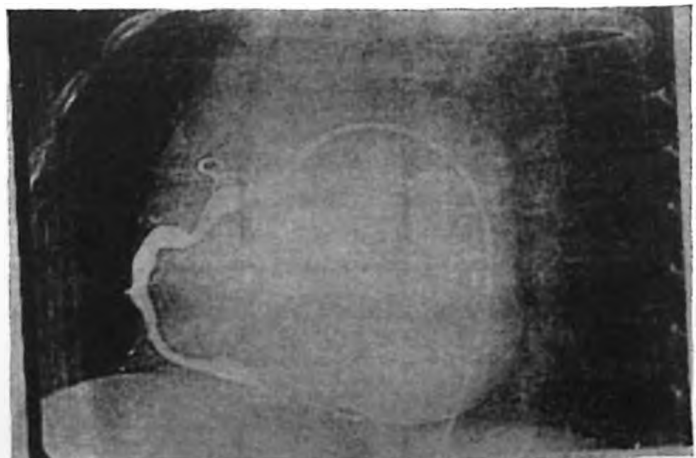

Fig. 2b. Coronary artery angiography demonstrating aneurysm formation in the right coronary artery without any stenotic lesion.

procedure, DSE was recently investigated as a non-invasive screening test in these patients, to document ischemia<sup>1</sup>.

Another study designed to determine the feasibility of performing exercise stress echocardiography in children diagnosed with coronary abnormalities secondary to KD was performed involving 28 children aged 6 to 16 years. All had acute KD one to 10 years before the study, and coronary artery abnormalities were identified during previous echocardiographic imaging. Two patients developed new exercise-induced wall motion abnormalities that corresponded to angiographically defined critical stenosis of the left anterior descending coronary artery, meaning that among patients with coronary artery involvement resulting from KD, exercise stress echocardiography is a safe, noninvasive procedure and may identify children with myocardial ischemia previously detected with ECG stress test alone<sup>7</sup>.

In conclusion, DSE appears to be a feasible, safe, and useful modality for the noninvasive assessment of flow-limiting stenosis in the pediatric population and can be used serially in the routine follow-up and risk stratification in children at risk for coronary events<sup>1</sup>. DSE has some limitations in discriminating particular regions of ischemia when multiple ventricular segments are involved and when the imaging is suboptimal. It can be applied using minimal additional resources in an otherwise functioning echocardiography laboratory and, with appropriate training, can achieve clinical results

comparable with those of large-scale multicenter trials. Ongoing improvements in technology and the development of new reagents such as myocardial contrast agents hold promise for further advancements in the near future<sup>8</sup>.

#### REFERENCES

1. Pahl E, Duffy CE, Chaudhry FA. The role of stress echocardiography in children. *Echocardiography* 2000; 17: 507-512.
2. Kimball TR, Witt SA, Daniels SR. Dobutamine stress echocardiography in the assessment of suspected myocardial ischemia in children and young adults. *Am J Cardiol* 1997; 79: 380-384.
3. Noto N, Ayusawa M, Krasava K, et al. Dobutamine stress echocardiography for detection of coronary artery stenosis in children with Kawasaki disease. *J Am Coll Cardiol* 1996; 27: 1251-1257.
4. Fukushige J, Takahashi N, Ueda K, Hijii T, Igarashi H, Ohshima A. Long-term outcome of coronary abnormalities in patients after Kawasaki disease. *Pediatr Cardiol* 1996; 17: 71-76.
5. Capannari TE, Daniels SR, Meyer RA, Schwartz DC, Kaplan S. Sensitivity, specificity and predictive value of two-dimensional echocardiography in detecting coronary artery aneurysms in patients with Kawasaki disease. *Am Coll Cardiol* 1986; 7: 355-359.
6. Kato H, Sugimura T, Akagi T, et al. Long-term consequences of Kawasaki disease. A 10- to 21-year follow-up study of 594 patients. *Circulation* 1996; 94: 1379-1386.
7. Pahl E, Sehgal R, Chrystof D, et al. Feasibility of exercise stress echocardiography for the follow-up children with coronary involvement secondary to Kawasaki disease. *Circulation* 1995; 91: 122-126.
8. Usher BW Jr, O'Brien TX. Recent advances in dobutamine stress echocardiography. *Clin Cardiol* 2000; 23: 566-570.