

Surgical outcome of congenital valvar aortic stenosis

Huda Elshershari¹, Dursun Alehan¹, Metin Demircin², İlhan Paşaoğlu², Arman Bilgiç¹

¹Cardiology Unit, Department of Pediatrics and ²Department of Cardiovascular Surgery, Hacettepe University Faculty of Medicine, Ankara, Turkey

SUMMARY: Elshershari H, Alehan D, Demircin M, Paşaoğlu İ, Bilgiç A. Surgical outcome of congenital valvar aortic stenosis. Turk J Pediatr 2002; 44: 304-311.

Valvar aortic stenosis is a common congenital heart defect for which surgical procedures can be done with low risk except in infants whose conditions are seriously compromised. The purpose of this report was to present our experience with the results of surgical aortic valvotomy for congenital valvar aortic stenosis performed at our hospital.

The study group consisted of 24 patients, 3 females and 21 males, with ages ranging from 1 to 15.5 years (mean age 8.5 years), who underwent aortic valvotomy for valvar aortic stenosis. The case records of all the patients were retrospectively reviewed. They were followed for 1-10.5 years (mean 5.02±2.38 years) after relief of aortic stenosis, and were scheduled for reevaluation.

Sixteen of the 24 patients were recatheterized and 15 (93.7%) were found to have aortic regurgitation on angiography. Peak systolic pressure gradients (mean±SD) were 65.9±19.5 mmHg before and 36.7±14.8 mmHg (p<0.05) after the operation. Of the 24 patients, 45.8% had a new postoperative diastolic murmur. Twenty patients (83.3%) had residual stenosis and three (12.5%) had recurrent stenosis. Two patients (8.3%) had undergone reoperation six to seven years after the initial aortic valvotomy, and most of the others will require reoperation in the future. No sudden deaths occurred in this series.

Timely relief of obstruction prevents sudden death and produces symptomatic improvement in valvar aortic stenosis, but aortic valvotomy is only a palliative measure.

Key words: congenital heart defect, valvar aortic stenosis, surgical aortic valvotomy.

Congenital aortic stenosis occurs in 3-6% of patients with congenital heart disease^{1,2}. Left ventricular outflow tract obstruction is most frequently at the valvular level, being observed in over 50% of the children who initially have findings of aortic stenosis^{3,4}. It is a progressive disorder, and the worsening may be due to the fact that the stenosis is becoming more severe. Thickening and increased rigidity of the valve tissue and varying degrees of diminished commissural separation comprise the basic malformation¹. The occurrence of sudden death in young patients with isolated congenital aortic stenosis is well recognized. Campbell⁵ reported an annual sudden death rate of 0.9% in children with this lesion.

Incision of congenitally fused aortic valve commissures can be dramatically beneficial in relieving aortic stenosis. Aortic valvotomy under direct vision was first described in 1956^{6,7}, and accepted as a palliative operation that provides initial benefit by decreasing risk of sudden death, but it is usually followed by an increasing incidence of reoperation. Most reported series conclude that all patients treated with valvotomy will ultimately require aortic valve replacement⁸⁻¹¹. In the First Natural History Study of Congenital Heart Defects, the incidence of bacterial endocarditis was high for patients with aortic stenosis and it was greater in patients who underwent surgical aortic valvotomy¹².

To evaluate the effectiveness of the operation, we reviewed our experience with 24 consecutive children who underwent aortic valvotomy. In this study the clinical records of all the patients were retrospectively reviewed, and they were scheduled for reevaluation.

Material and Methods

Twenty-eight patients underwent surgical intervention for congenital aortic stenosis at the İhsan Dođramacı Children's Hospital. One 19-day-old infant died during the operation and three patients aged 21 days, 75 days and 10.5 months died after the operation, yielding an operative mortality of 14%. The remaining 24 patients who had neither septal defect nor additional valvular lesions were included in this series. There were 21 boys and 3 girls whose mean age was 8.5 years (range 1 to 15.5 years) at the time of the operation.

Symptoms were present in three cases of the study group at the last evaluation after surgery. Determination of functional classification in accordance with the New York Heart Association's (NYHA) criteria revealed 21 patients to be in Class I, two patients in Class III and one patient in class IV (Table I).

Table I. Clinical Features of the Study Patients (Survivors) at the Last Evaluation

| Pt no. | Age (yrs) | Sex (M/F) | Follow-up period (yrs) | NYHA class |
|--------|-----------|-----------|------------------------|------------|
| 1 | 26 | M | 10.5 | I |
| 2 | 22 | M | 7.5 | I |
| 3 | 21 | M | 8.5 | I |
| 4 | 21 | M | 7 | IV |
| 5 | 19 | M | 6 | I |
| 6 | 16 | M | 2 | I |
| 7 | 15 | M | 7 | I |
| 8 | 14 | M | 4 | III |
| 9 | 14 | M | 1 | I |
| 10 | 14 | M | 1 | I |
| 11 | 13 | M | 5.5 | I |
| 12 | 13 | M | 4.5 | I |
| 13 | 12 | F | 6.5 | III |
| 14 | 12 | F | 4 | I |
| 15 | 11 | M | 4.5 | I |
| 16 | 11 | M | 4 | I |
| 17 | 11 | M | 5.5 | I |
| 18 | 10 | M | 3.5 | I |
| 19 | 10 | M | 4 | I |
| 20 | 9 | M | 7.5 | I |
| 21 | 9 | M | 2.5 | I |
| 22 | 8 | M | 7 | I |
| 23 | 8 | F | 4 | I |
| 24 | 6 | M | 3 | I |

NYHA: New York Heart Association.

Preoperative peak systolic pressure gradients ranged from 45 to 128 mmHg, with a mean value of 65.86 ± 19.49 mmHg. All but eight patients underwent preoperative cardiac catheterisation. Follow-up data by clinical evaluation in our Cardiology Department were obtained for all of the patients from 1-10.5 years (mean 5.02 ± 2.38 years) postoperatively. The follow-up was based essentially on physical examination, electrocardiogram (ECG), chest X-ray and echo Doppler examination. Left ventricular hypertrophy was assessed by ECG using the criteria established by Romhilt and Estes¹³. Cardiomegaly was reported if the cardiothoracic ratio was greater than 0.5.

Sixteen patients were recatheterized. Outflow tract gradients were calculated from left ventricular aortic pullback tracings, and the presence of aortic regurgitation was confirmed or ruled out by aortic root angiography. Associated lesion was present in two patients: one patient (No.9) had aortic coarctation and the other (No.14) had subaortic ridge. Bicuspid aortic valve was present in 14 patients (58.3%) and none had unicuspid valve. Aortic balloon valvotomy was not performed in this series.

An M-mode echocardiogram with two-dimensional echocardiographic guidance was obtained at the mid-left ventricular cavity level. Measurements of left ventricular cavity size, ventricular septum, and posterior wall were made at end diastole and end systole. Offline system was used for calculation of ejection and shortening fraction¹⁴. Continuous-wave Doppler examination of the aortic valve gradient was performed. The aortic stenosis jet was recorded from suprasternal transducer position. The peak instantaneous echocardiographic aortic valve gradient (echograd) was calculated using the simplified Bernoulli equation¹⁴.

In this study, we used color Doppler echocardiography for non-invasive evaluation of aortic regurgitation. The Doppler examinations were performed with a Toshiba sonolayer SSH-60A Doppler echocardiograph equipped with 2.5, 3.75 and 5 MHz phased-array transducers.

Color Doppler Examination

The regurgitant jet was studied in the parasternal long-axis view. Aortic regurgitation was considered to be present when an abnormal diastolic flow (a mosaic pattern indicating turbulent flow) originating from the aortic valve was visualized in the left ventricle¹⁵⁻¹⁷.

Cardiac Catheterization

The peak to peak gradient across the left ventricular outflow tract (cathgrad) was measured by catheter pullback. The presence and severity of aortic regurgitation was assessed from biplane angiography. Aortic root angiography was performed with injection of 1 ml/kg contrast material in the left and right anterior oblique view. The degree of aortic regurgitation was graded independently from the echocardiographic findings by the method of Grossman¹⁸ as follows:

Grade I, faint opacification of part of the left ventricle which clears with each systole; Grade II, opacification of the left ventricle to a degree less than that in the aorta; Grade III, opacification of the left ventricle equal to that of the aorta; Grade IV, complete dense opacification of the left ventricle in one beat with a constant density greater than that in the aorta.

Mortality was defined in terms of perioperative and late death. Perioperative death occurred within 30 days of valvotomy.

Statistical Methods

Normally distributed data are presented as mean \pm standard deviation. Non-normally distributed data are described as median and range. Comparison of transaortic valve gradient before and after aortic valvotomy was performed using t-tests for paired samples. A p value of <0.05 was considered significant.

Results

Reintervention included reoperation in two patients (8.3%). One patient had severe aortic regurgitation, and an aortoplasty was performed seven years after surgical aortic valvotomy, while the other patient required aortic valve replacement six years after initial surgical intervention for asymptomatic restenosis.

The ECG was normal in 15 patients, revealed a strain pattern in two patients, and left ventricular hypertrophy without strain in nine patients. Of these, one had ventricular extrasystoles and Holter monitoring had demonstrated the presence of multiple couplets and triplets, therefore antiarrhythmic therapy was prescribed. Radiographic measurement revealed 17% with cardiomegaly, and 29.1% had dilatation of the ascending aorta.

Hemodynamic Data

Heart catheterisation was done preoperatively in 18 and postoperatively in 16 patients of the study group. The left ventricle could not be entered preoperatively in nine and postoperatively in one patient. The mean preoperative aortic cathgrad of 78.2 ± 33.13 mmHg (range 45-128 mmHg, n=9) was decreased to 35 ± 8.98 mmHg (range 20-55 mmHg, n=16) after surgery.

Aortic regurgitation assessed angiographically before aortic valvotomy (n=18) was of grade I in 4, II in 1, IV in 1 patient, and absent in the remainder (67%). Postoperative assessment (n=16) revealed aortic regurgitation of grade I in 2, II in 3, III in 7, IV in 3 and absence in 1 patient (Table II).

Table II. Assessment of Aortic Regurgitation (AR) and Transaortic Gradient Before Aortic Valvotomy and at the Last Follow-up

| No. | Preoperative | | Postoperative | |
|-----|--------------|-----------------|---------------|-----------------|
| | AR | Aortic gradient | AR | Aortic gradient |
| 1 | No | 70* | No | 10* |
| 2 | No | 67** | No | 22* |
| 3 | No | 115* | No | 70** |
| 4 | No | 60* | IV | 38 |
| 5 | No | 51** | III | 35 |
| 6 | No | 80** | No | 40* |
| 7 | I | 50 | III | 30 |
| 8 | No | 70** | I | 30* |
| 9 | No | 46** | II | 30 |
| 10 | II | 65 | II | 50* |
| 11 | No | 68* | III | 35 |
| 12 | No | 68** | No | 45* |
| 13 | No | 128 | II | 24* |
| 14 | I | 45 | II | 38 |
| 15 | No | 90 | III | 35 |
| 16 | No | 82 | III | 30 |
| 17 | No | 100 | I | 55 |
| 18 | I | 89** | III | 30 |
| 19 | I | 114 | II | 40* |
| 20 | No | 80** | II | 32 |
| 21 | No | 80** | I | 35 |
| 22 | No | 60* | III | 50 |
| 23 | No | 76* | IV | 20 |
| 24 | IV | 65 | IV | 25 |

* Gradient as detected by echocardiography because cardiac catheterization was not performed.

** Gradient as detected by echocardiography because left ventricle could not be entered during catheter.

No: aortic regurgitation is not evident.

Echocardiographic Findings

All of the survivors were assessed echocardiographically during follow-up, and the mean echograd was 36.65 ± 14.78 mmHg (range 20-70 mmHg), whereas preoperative mean

echograd was 65.86 ± 19.49 mmHg ($t=6.66$, $P=0.000$). Figure 1 demonstrates the transaortic gradient assessed either by echocardiography or cardiac catheterisation before aortic valvotomy and at last evaluation after the surgical intervention.

The recurrence of significant stenosis was evident in three patients (No: 3, 16, 17) after a follow-up period of 8.5, 4, and 5.5 years, respectively. In this series, restenosis rate was found to be 12.5%. However, 20 patients had residual aortic stenosis of mild-to-moderate degree (systolic gradient between 20 and 50 mmHg), and residual gradient was absent in only one patient (4%).

Postoperative aortic regurgitation graded by color Doppler echocardiography was mild in 6, moderate in 10, severe in 1 and absent in the rest. There was agreement between angiographic and color Doppler assessment of aortic regurgitation in 14 of 16 cases (Table III). Echocardiography performed before the initial intervention showed aortic regurgitation in four of these patients. In this study, approximately 25% of patients had aortic regurgitation before surgical valvotomy, whereas postoperative aortic regurgitation was evident in 71% of these patients (Fig. 2). Although aortic regurgitation causes left ventricular volume overload that may result in left ventricular dysfunction, this was not evident in this review.

Figure 3 illustrates the number of cases that had progression or new development of aortic regurgitation postoperatively.

Table III. Echocardiographic and Angiographic Evaluation of AR in the Study Group

| Case no. | Color doppler | Aortography |
|----------|---------------|-------------|
| 1 | NO | - |
| 2 | NO | - |
| 3 | NO | NO |
| 4* | III | IV |
| 5 | III | III |
| 6 | NO | - |
| 7 | III | III |
| 8 | I | - |
| 9 | II | II |
| 10 | II | - |
| 11 | III | III |
| 12 | NO | - |
| 13 | II | - |
| 14 | III | II |
| 15 | III | III |
| 16 | III | III |
| 17 | NO | I |
| 18 | III | III |
| 19 | II | - |
| 20 | I | II |
| 21 | NO | I |
| 22 | III | III |
| 23 | IV | IV |
| 24 | III | IV |

* Aortoplasty was performed due to severe aortic regurgitation which developed after valvotomy.

NO: aortic regurgitation (AR) is not evident.




Fig. 1. Assessment of transaortic gradient before and after surgery at the last follow-up.

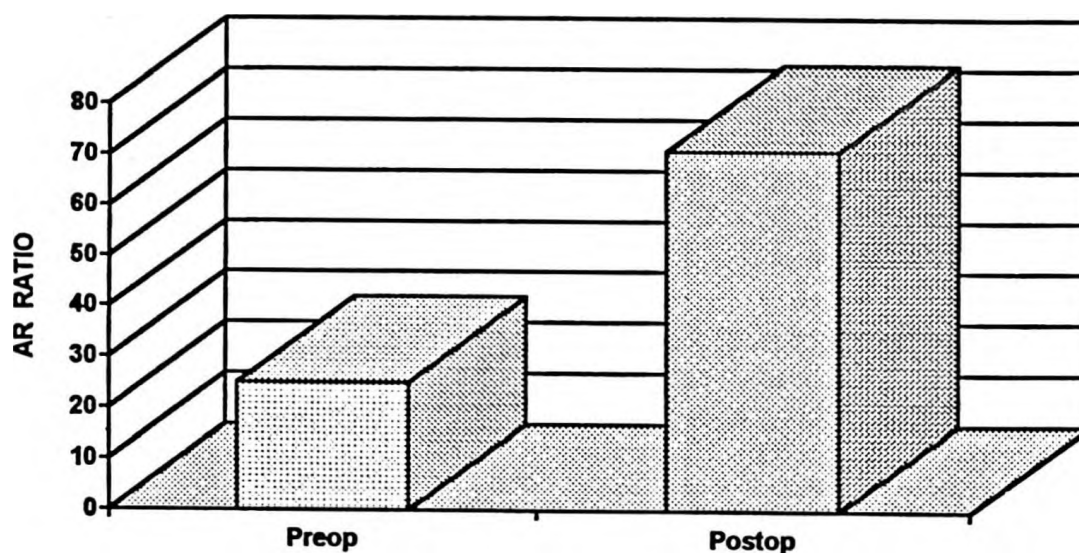


Fig. 2. The percent of aortic regurgitation (AR) detected by echocardiography or aortography after valvotomy.

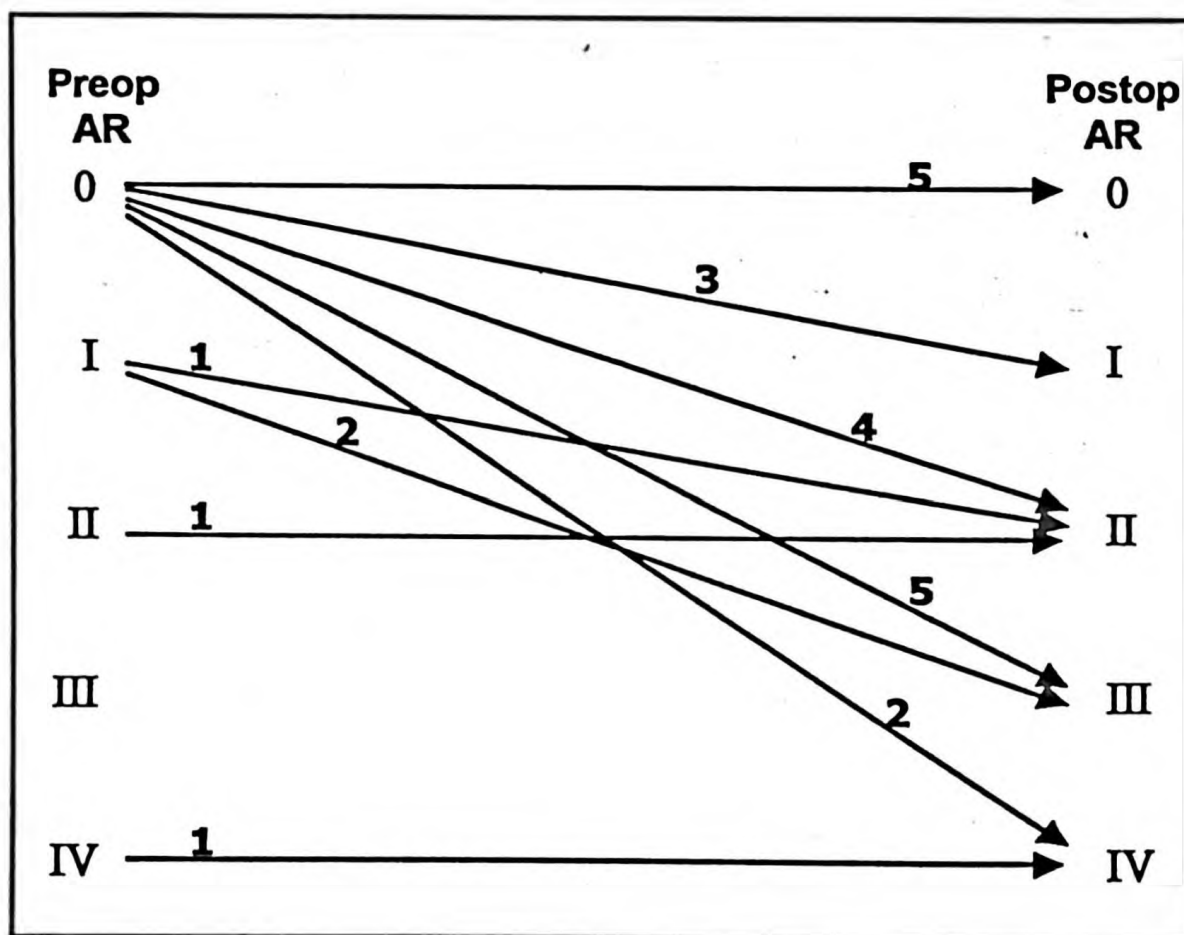


Fig. 3. Evaluation of aortic regurgitation (AR) among the study group during preoperative and postoperative period at the last evaluation (the number of cases is shown).

Discussion

Sudden death in children with congenital aortic stenosis constitutes the major indication for hemodynamic study and surgical intervention. Sudden death has been reported to occur 1-19% of these patients¹⁹⁻²⁰. The absence of sudden

death in this study confirms the safety and timely relief of aortic stenosis. Although open aortic valvotomy is well established with a low surgical mortality, it is still regarded as palliative therapy because most patients require reoperation, since aortic regurgitation may

occur and restenosis is common. Lababidi and associates²¹ first reported that percutaneous balloon aortic valvuloplasty might be an alternative method of treating aortic stenosis by minor tearing of the aortic commissures and stretching of the valve leaflets. Others have also reported that valvuloplasty can successfully treat valvular aortic stenosis in children²²⁻²³.

Reports of surgical results have indicated that reoperation will be necessary in a significant number of patients⁸⁻¹¹. Two of our 24 patients (8.3%) have, thus far, needed reoperation six to seven years after the initial operation, and most of the other patients are likely to need further surgery in the future. Most of these reoperations will be for cardiac decompensation secondary to iatrogenic aortic regurgitation, residual stenosis or recurrent stenosis. Postoperative reductions in aortic valve gradient were significant on paired testing, and mild-to-moderate residual aortic systolic pressure gradient (20-70 mmHg) was recorded in 95.8% of this series. The stiffness and abnormal configuration found in most of these valves may account in part for the frequency of residual gradients²⁴.

Postoperative gradients of 50 mmHg or greater predispose patients to sudden death. Hence, annual non-invasive testing is recommended for patients with either residual stenosis or aortic regurgitation¹¹. Aortic stenosis is a progressive disease²⁵, and progression of the obstruction is a well known late complication in postsurgical patients⁴. This was also observed in this study. The reason for the commonly observed progression of disease may lie, in part, in the configuration of the valve and the degree of valve dysplasia¹⁰. In our series, postoperative regular echocardiographic examinations revealed that the transaortic gradient increased significantly in three patients (No. 3, 16, 17); one of them required aortic valve replacement, but his parents would not give their consent for the operation.

Twenty-one (87.5%) of the study patients were clinically asymptomatic at postoperative follow-up despite well known iatrogenic incompetence, and residual and recurrent stenosis. Similar findings have been reported by others²⁰. One symptomatic patient (No. 4) with effort intolerance was restudied, and angiography showed severe aortic regurgitation. In this case, a second operation (aortoplasty) was performed.

The other two patients (No. 8, 13) with angina had residual gradients of 30 and 24 mmHg, respectively, with evidence of mild-to-moderate aortic regurgitation.

The most important technical complication of aortic valvotomy is the production of aortic regurgitation. Approximately 8% of preoperative patients had an early diastolic murmur of regurgitation, whereas 46% of our patients developed a new diastolic murmur postoperatively. Similar figures have been noted by others^{26,27}. Postoperative catheterisation was performed in 16 (66.6%) patients and 93.7% of them had angiographic evidence of aortic regurgitation. In 63%, the degree of aortic regurgitation was found to be moderate or severe. Of these, two patients showed progression of preoperative mild aortic regurgitation to moderate degree postoperatively at the last follow-up. Evaluation of all patients after valvotomy by Doppler echocardiography or angiography revealed an aortic regurgitation ratio of more than 70%. The high incidence of aortic regurgitation reflects a surgical aim to relieve stenosis maximally and prevent sudden death with acceptance of some regurgitation. In contrast, Chartrand and colleagues²⁸ reported much lower figures of postoperative aortic insufficiency (12%) and they postulated that this finding was related to the careful limitation of the commissurotomy. On the other hand, 24% of their patients required a second intervention due to recurrence and progression of valvular stenosis, and the rate of sudden death in their series was 3% at the postoperative follow-up.

Bacterial endocarditis has been considered an important risk in the setting of aortic stenosis. Gersony and associates¹² reported that the incidence of bacterial endocarditis in patients with aortic stenosis managed surgically was greater than seen in those managed medically, and they suggested that development of aortic regurgitation and persistence of some postoperative gradient might have contributed to the development of bacterial endocarditis. They concluded that the increased incidence in patients with aortic stenosis after surgical valvotomy was a function of severity and not a function of surgery¹². However, in our study group bacterial endocarditis was not observed in any patient. Open aortic valvotomy for relief of congenital aortic valve obstruction in children and adolescents is associated with a low

mortality^{4,24}. The results obtained in this group of patients indicate that surgical aortic valvotomy can be performed with an acceptable operative risk. However, surgical repair of aortic stenosis is associated with a high risk in infants, because they have a more severe form of the disease^{29,30}. The low operative mortality and long-term relief of stenosis and symptoms provided by open aortic valvotomy in patients aged more than one year establishes it as the standard procedure. However, aortic insufficiency in these patients is progressive, and valve replacement may eventually be required. Aortic insufficiency was the indication for valve replacement noted by Sandor and his associates²⁰. They concluded that reoperation had a higher risk and that results were not as satisfactory as those for the first operation.

This natural history of surgical aortic valvotomy provides a framework for comparison with long-term results of balloon aortic valvotomy. Gatzoulis et al.³¹ compared the contemporary results of balloon dilatation and surgery for valvular aortic stenosis in infants and children. They considered both balloon and surgical valvotomy palliative forms of treatment, as the majority of these patients are likely to require aortic valve replacement later in life. Balloon dilatation offers the additional attraction of deferring the definitive surgery and preserving the surgical field, and the hospital stay is significantly shorter in the balloon dilatation group, with obvious financial benefits. Justo et al.³² compared the degree and rate of progression of aortic regurgitation, relief of obstruction, complications and mortality after balloon aortic valvotomy versus surgical valvotomy. Their results suggested that progression of aortic regurgitation, and acute and late reduction of gradients were similar for both approaches.

We conclude that although timely relief or left ventricular outflow tract obstruction in children prevents sudden death and provides excellent symptomatic relief, the operation is only palliative. The common occurrence of postoperative aortic incompetence, residual aortic stenosis, persistence of cardiomegaly and ECG abnormalities, and the frequent need for reoperation demonstrate that some congenitally deformed valves cannot be satisfactorily reconstructed for the long-term with standard operative techniques. The goal of aortic valvotomy is to facilitate the child's growth to the point where a prosthetic valve may be inserted.

REFERENCES

1. Friedman WF. Aortic stenosis. In: Emmanouilides GC, Riemenschneider TA, Allen HD, Gutjesell HP (eds). *Moss and Adams Heart Disease in Infants, Children and Adolescents* (5th ed). Baltimore: Williams and Wilkins Co; 1992; 1087-1107.
2. Stewart JR, Paton BC, Blount G, Swan H. Congenital aortic stenosis: ten to 22 years after valvulotomy. *Arch Surg* 1978; 113: 1248-1252.
3. Conkle DM, Jones M, Morrow AG. Treatment of congenital aortic stenosis. *Arch Surg* 1973; 107: 649-651.
4. Chiariello L, Agosti J, Vald P, Subramanian S. Congenital aortic stenosis: experience with 43 patients. *J Thorac Cardiovasc Surg* 1976; 72: 182-193.
5. Campbell M. The natural history of congenital aortic stenosis. *Br Heart J* 1968; 30: 514-526.
6. Lewis FJ, Shumway NE, Niazi SA, Benjamin RB. Aortic valvulotomy under direct vision during hypothermia. *J Thorac Surg* 1956; 32: 481-499.
7. Swan H, Korz A. Direct vision trans-aortic approach to the aortic valve during hypothermia: experimental observations and report of a successful clinical case. *Ann Surg* 1956; 144: 205-214.
8. Hsieh KS, Keane JF, Nadas AS, Bernhard WF, Castaneda AR. Long-term follow-up of valvotomy before 1968 for congenital aortic stenosis. *Am J Cardiol* 1986; 58: 338-341.
9. Ankeney JL, Tzeng TS, Liebman J. Surgical therapy for congenital aortic valvular stenosis. *J Thorac Cardiovasc Surg* 1983; 85: 41-48.
10. Dobell AR, Bloss RS, Gibbons JE, Collins GF. Congenital valvular aortic stenosis: surgical management and long-term results. *J Thorac Cardiovasc Surg* 1981; 81: 916-920.
11. DeBoer DA, Robbins RC, Maron BJ, McIntosh CL, Clark RE. Late results of aortic valvotomy for congenital valvar aortic stenosis. *Ann Thorac Surg* 1990; 50: 69-73.
12. Gersony WM, Hayes CJ, Driscoll DJ, et al. Bacterial endocarditis in patients with aortic stenosis, pulmonary stenosis, or ventricular septal defect. *Circulation* 1993; 87 (Suppl): I121-I126.
13. Romhilt DW, Estes EH Jr. A point-score system for ECG diagnosis of left ventricular hypertrophy. *Am Heart J* 1968; 75: 751-758.
14. Feigenbaum H. Echocardiographic evaluation of cardiac chambers. In: Feigenbaum H (ed). *Echocardiography* (5th ed). Philadelphia: Lea & Febiger; 1994: 134-180.
15. Masuyama T, Kodama K, Kitabatake A, et al. Noninvasive evaluation of aortic regurgitation by continuous wave Doppler echocardiography. *Circulation* 1986; 73: 460-466.
16. Touche T, Prasquier R, Nitenberg A, Zuttere D, Gourgon R. Assessment and follow-up of patients with aortic regurgitation by an updated Doppler echocardiographic measurement of the regurgitant fraction in the aortic arch. *Circulation* 1985; 72: 819-824.
17. Perry GJ, Helmcke F, Nanda NC, Byard C, Soto B. Evaluation of aortic insufficiency by Doppler color flow mapping. *J Am Coll Cardiol* 1987; 9: 952-959.
18. Grossman W. Profiles in valvular heart disease. In: Grossman W (ed). *Cardiac Catheterization and Angiography* (3rd ed). Philadelphia: Lea & Febiger; 1986: 359-383.

19. Keane JF, Driscoll DJ, Gersony WM. Et al. Second natural history study of congenital heart defects: results of treatment of patients with aortic valvar stenosis. *Circulation* 1993; 87 (Suppl): 16-27.
20. Sandor GG, Olley PM, Trusler GA, Williams WG, Rowe RD, Morch JE. Long term follow up of patients after valvotomy for congenital valvular aortic stenosis in children. *J Thorac Cardiovasc Surg* 1980; 80: 171-176.
21. Lababidi Z, Wu JR, Walls JT. Percutaneous balloon aortic valvuloplasty; results in 23 patients. *Am J Cardiol* 1984; 53: 194-197.
22. O'Connor BK, Beekman RH, Rocchini AP, Rosenthal A. Intermediate-term effectiveness of balloon valvuloplasty for congenital aortic stenosis. *Circulation* 1991; 84: 732-738.
23. Witsenburg M, Cromme-Dijkuis A, Frohn-Mulder IM, Hess J. Short and midterm results of balloon valvuloplasty for valvular aortic stenosis in children. *Am J Cardiol* 1992; 69: 945-950.
24. Ellis FH, Ongley PA, Kirklin JW. Results of surgical treatment for congenital aortic stenosis. *Circulation* 1962; 25: 29-38.
25. Kitchiner D, Jackson M, Walsh K, Peart I, Arnold R. The progression of mild congenital aortic valve stenosis from childhood into adult life. *Int J Cardiol* 1993; 42: 217-223.
26. Lawson RM, Bonchek LI, Menashe V, Starr A. Late results of surgery for left ventricular outflow tract obstruction in children. *J Thorac Cardiovasc Surg* 1976; 71: 334-341.
27. Shackleton J, Edwards FR, Bickford BJ, Jones RS. Long-term follow-up of congenital aortic stenosis after surgery. *Br Heart J* 1972; 34: 47-51.
28. Chartrand CC, Saro-Servando E, Vobecky JS. Long-term results of surgical valvuloplasty for congenital valvar aortic stenosis in children. *Ann Thorac Surg* 1999; 68: 1356-1360.
29. Ettedgui JA, Tallman-Eddy T, Neches WH, et al. Long-term results of survivors of surgical valvotomy for severe aortic stenosis in early infancy. *J Thorac Cardiovasc Surg* 1992; 104: 1714-1720.
30. Gundry SR, Behrendt DM. Prognostic factors in valvotomy for critical aortic stenosis in infancy. *J Thorac Cardiovasc Surg* 1986; 92: 747-754.
31. Gatzoulis MA, Rigby ML, Shinebourne EA, Redington AN. Contemporary results of balloon valvuloplasty and surgical valvotomy for congenital aortic stenosis. *Arch Dis Child* 1995; 73: 66-69.
32. Justo RN, McCrindle BW, Benson LN, Williams WG, Freedom RM, Smallhorn JF. Aortic valve regurgitation after surgical versus percutaneous balloon valvotomy for congenital aortic valve stenosis. *Am J Cardiol* 1996; 77: 1332-1338.