

Metastatic endodermal sinus tumor: CT appearances

Bilgehan Yalçın¹, M. Tezer Kutluk¹, Macit Arıyürek², Safiye Göğüş³, Münevver Büyükpamukçu¹

¹Department of Pediatric Oncology, Institute of Oncology and Departments of ²Radiology, and ³Pediatric Pathology, Hacettepe University Faculty of Medicine, Ankara, Turkey

SUMMARY: Yalçın B, Kutluk MT, Arıyürek M, Göğüş S, Büyükpamukçu M. Metastatic endodermal sinus tumor: CT appearances. Turk J Pediatr 2002; 44: 343-345.

A one-week-old boy had undergone resection of a sacrococcygeal benign cystic teratoma. At the age of 12 months, he had a serum alpha-fetoprotein level of 139,000 IU/ml and a recurrent pelvic mass which was removed, and the microscopic examination revealed endodermal sinus tumor. Postoperatively, massively enlarged inguinal lymph nodes and abdominal distention developed. Computerized tomography displayed enlarged inguinal lymph nodes, metastatic lesions in the liver, and a pelvic recurrent mass. He received BEP (bleomycin, etoposide, cisplatin) chemotherapy regimen, and a complete remission was achieved with a normal serum alpha-fetoprotein. Close follow-up and serum alpha-fetoprotein monitoring are mandatory after the resection of a sacrococcygeal teratoma.

Key words: endodermal sinus tumor, sacrococcygeal teratoma, computerized tomography, alpha-fetoprotein.

In children the sacrococcygeal region is the most common location for nongonadal germ cell tumors⁵, and sacrococcygeal teratoma (SCT) is the most common tumor of the newborn¹. Although these tumors are mostly benign, some may contain immature elements and malignant transformation may develop. Here, we report a case with a resected mature SCT which recurred at the age of 12 months as an endodermal sinus tumor (EST) with extensive abdominal disease and rather extraordinary images on computerized tomography (CT).

Case Report

A one-week-old boy had been seen in another hospital due to a sacrococcygeal mass, at which time he had a preoperative serum alpha-fetoprotein (AFP) level over 300 IU/ml and had undergone a total excision of the mass together with the coccyx. Histopathological diagnosis had been benign cystic teratoma. At the age of 12 months he was admitted to the same hospital and a pelvic CT displayed a predominantly cystic, recurrent sacrococcygeal mass which was removed totally: histopathological examination revealed EST. Two weeks after the operation, abdominal distention, hepatomegaly and massively enlarged inguinal lymph nodes were

noted (Fig. 1) and he was referred to our hospital. The patient was reevaluated and an abdominal CT displayed a recurrent pelvic mass, inguinal enlarged lymph nodes and metastatic lesions in the liver (Figs. 2 and 3); serum AFP level was 139,000 IU/ml. Thoracic CT was normal and abdominal ultrasound findings were similar to abdominal CT. After receiving six cycles of BEP regimen (bleomycin, etoposide, cisplatin), abdominal CT displayed no evidence of tumor and serum AFP level was normal. However, in the following months, serum AFP level increased steadily, and the patient is still under treatment due to recurrent disease.

Discussion

The prognosis of SCTs depends on the age of the patient, surgical resectability of the primary tumor and the histological grading⁴. Patients under two months of age who have had a complete surgical excision have a favourable outlook, especially when the histological grading is low and tumor lacks malignant elements⁴. EST is the most common histological type of malignancy that develops within SCTs⁵. Recurrences occur in about 3% to 10% of cases and usually develop in about two years after the initial resection¹⁻³. The presence of a malignant

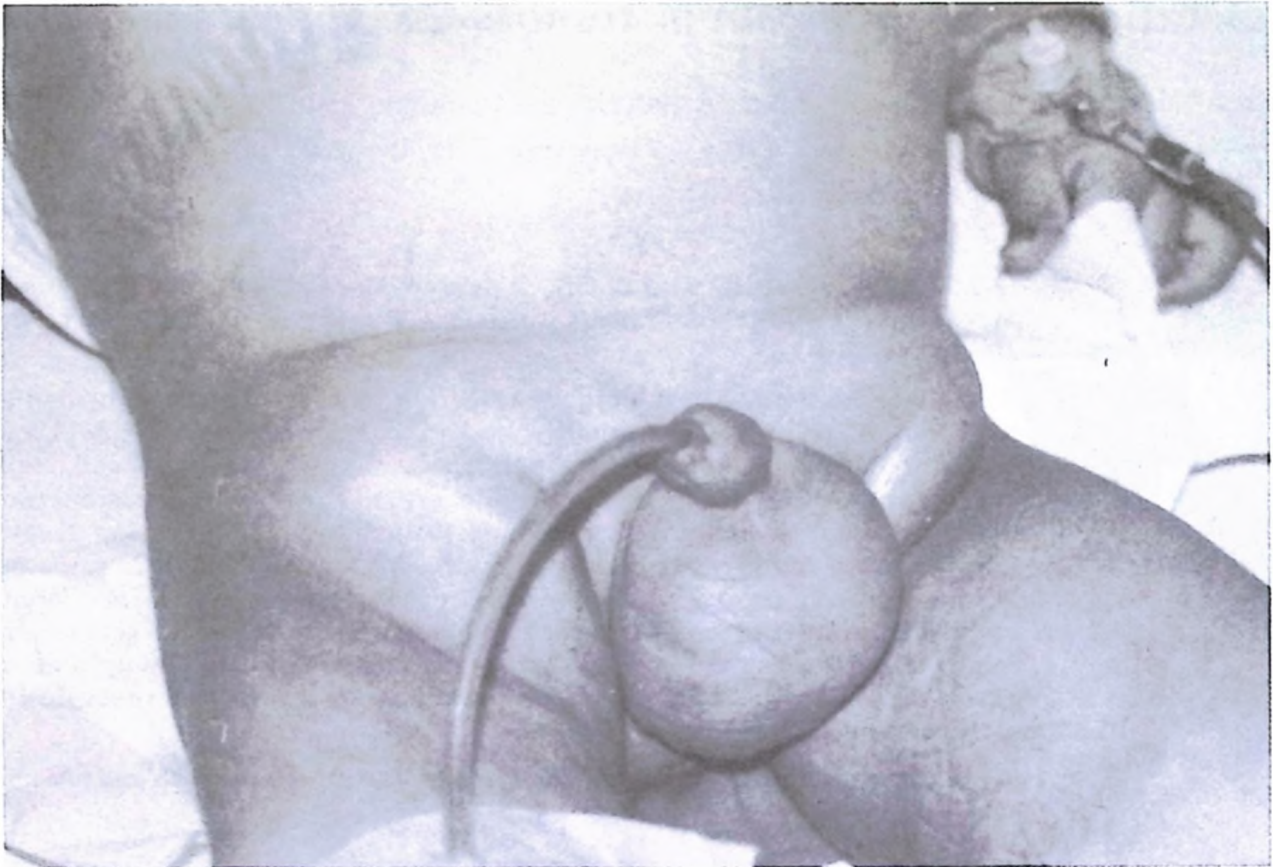


Fig. 1. Clinical appearance of the patient with abdominal distention and enlarged inguinal lymph nodes.

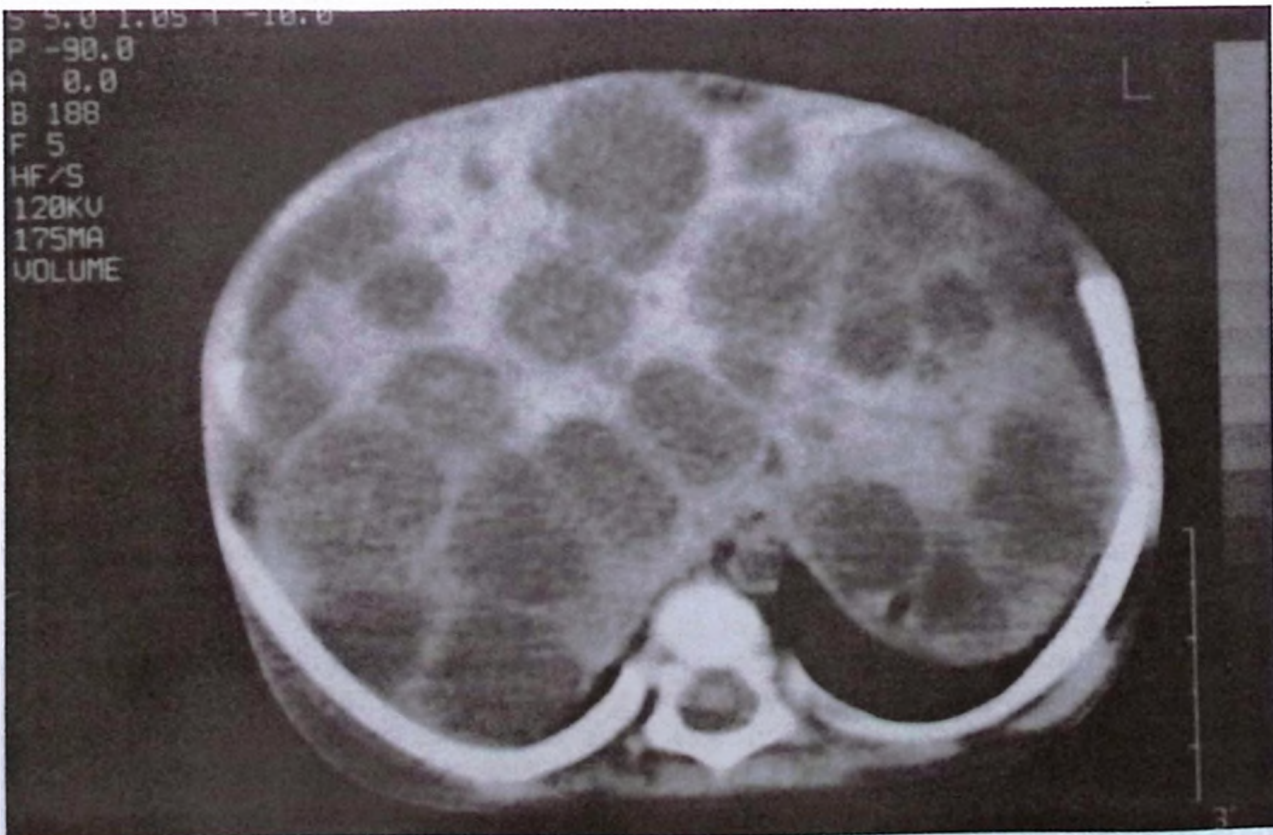

Fig. 2. Computerized tomography shows multiple metastatic lesions in the liver.

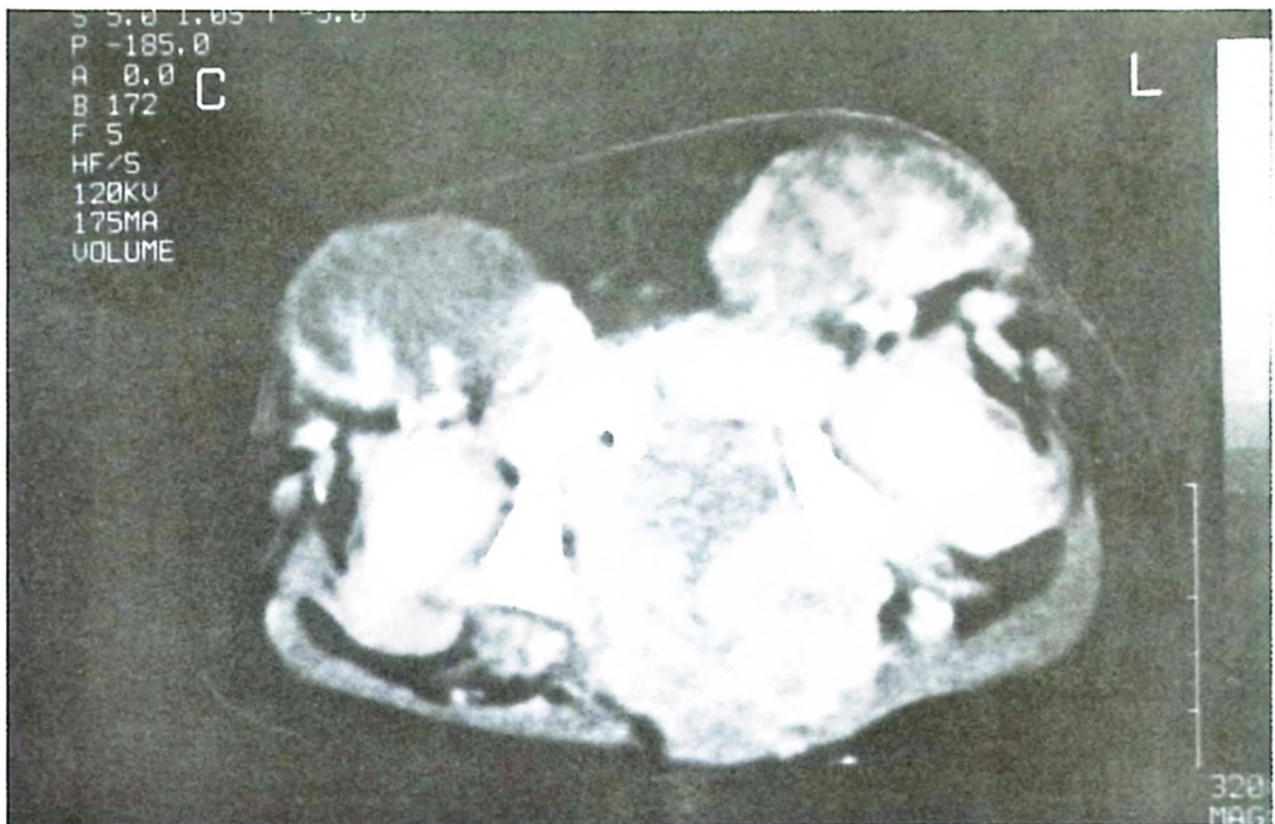


Fig. 3. Pelvic computerized tomography displays huge metastatic inguinal lymph nodes and a pelvic mass.

component is commonly associated with an elevated serum AFP level^{2,5}. In a newborn patient, it may be difficult to evaluate serum AFP level as a tumor marker since it is already elevated in the neonatal period.

Our patient was not under regular follow-up after the initial operation. We did not have information regarding initial preoperative radiologic or other investigations. The massively enlarged inguinal metastatic lymph nodes and the liver filled with multiple metastatic lesions made the CT images rather extraordinary. Clinically and radiologically, we achieved complete remission and serum AFP was normal after chemotherapy. The use of multiagent chemotherapy regimens has resulted in significant improvement in the prognosis for children with EST, and overall survival has improved significantly even in children with advanced disease. After total resection of a primary SCT, an elevated AFP level is a reliable marker for a recurrence of EST. Tumor recurrence could have been detected earlier if

our patient had been under regular follow-up previously. Close follow-up at least for three years with frequent physical examination, serum AFP monitoring and diagnostic imaging is necessary for all children who have undergone excision of SCT in the newborn period^{1,5}.

REFERENCES

1. Bilik R, Shandling B, Pope M, Thorner S, Weitzman S, Ein SH. Malignant benign neonatal sacrococcygeal teratoma. *J Pediatr Surg* 1993; 28: 1158-1160.
2. Davidoff AM, Hebra A, Bunin N, Shochat SJ, Schnauffer L. Endodermal sinus tumor in children. *J Pediatr Surg* 1996; 31: 1075-1079.
3. Hawkins E, Issacs H, Cushing B, Rogers P. Occult malignancy in neonatal sacrococcygeal teratomas. A report from a Combined Pediatric Oncology Group and Children's Cancer Group study. *Am J Pediatr Hematol Oncol* 1993; 15: 406-409.
4. Lanzkowsky P. *Manual of Pediatric Hematology and Oncology*. San Diego: Academic Press; 2000: 617-641.
5. Skinner Ma. Germ cell tumors. In: Oldham KT, Colombani PM, Foglin RP (eds). *Surgery of Infants and Children: Scientific Principles and Practice*. Philadelphia: Lippincott-Raven Publishers; 1997: 653-662.