

## Generalized lichen planus in childhood: is dapsone an effective treatment modality?

Pınar Y. Başak<sup>1</sup>, Kayhan Başak<sup>2</sup>

<sup>1</sup>Department of Dermatology, Süleyman Demirel; University Faculty of Medicine and <sup>2</sup>Başak Pathology Laboratory, Isparta, Turkey

**SUMMARY:** Başak PY, Başak K. Generalized lichen planus in childhood: is dapsone an effective treatment modality? Turk J Pediatr 2002; 44: 346-348.

Childhood lichen planus is generally atypical in appearance, prolonged in duration and resistant to therapy. Moreover, the risk in administration of systemic drugs because of several adverse effects limits their use and effective therapy remains a problem in this age group. We report a case of generalized lichen planus in a nine-year-old boy with oral mucosa and nail involvement who was treated with dapsone.

*Key words.* lichen planus, childhood, treatment, dapsone.

Lichen planus (LP) is a rare inflammatory disease of unknown etiology and its incidence peaks in adulthood. Only 2% to 3% of all cases were reported to be described in children under 14 years, and they may present atypical clinical findings<sup>1-4</sup>. Mucosal involvement and nail abnormalities are rare and management of treatment is difficult in the pediatric patient<sup>5,6</sup>. Generalized lichen planus was observed in a nine-year-old boy and treated with dapsone during a period of approximately one year.

### Case Report

A nine-year-old boy presented with a three-month history of itchy lesions on the trunk and limbs. There was no family, atopy, drug or vaccination history except for unsuccessful response to systemic steroids previously used for his skin lesions. On examination, brown to violaceous, slightly scaly papules all over the trunk, and coalescing in the lumbar region and limbs were observed (Fig. 1a). Besides leukokeratotic buccal mucosal involvement, the first toenails of both feet appeared dull and opaque with slight longitudinal ridging (Fig. 2a, b). Laboratory analysis including complete blood count, urinalysis, biochemical and hormonal parameters as well as markers for hepatitis were in normal ranges. Mycologic examination of the toenails was

negative and radiology revealed no constitutional abnormalities. Histopathologic findings of the biopsy from the skin lesions were consistent with LP (Fig. 3). Dapsone, 50 mg daily (1.5 mg/kg/day) was started. Itching subsided within one month and disappeared in the second month of treatment. Skin lesions, especially on the trunk, started flattening after three months. At the end of eight months of therapy, there were still active lesions present on the limbs. The dosage was increased to 75 mg daily (2.5 mg/kg/day) and new lesions stopped appearing within two months. The lesions were totally cleared at the end of five months of treatment with the same dosage, leaving hyperpigmented macules on the lower extremities (Fig. 1b).

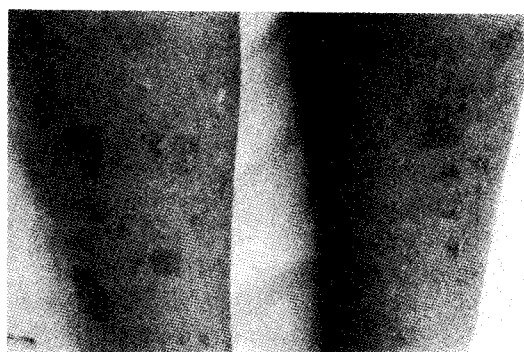


Fig. 1a: Lesions on the legs before treatment.




Fig. 1b. Posttreatment view of the legs.

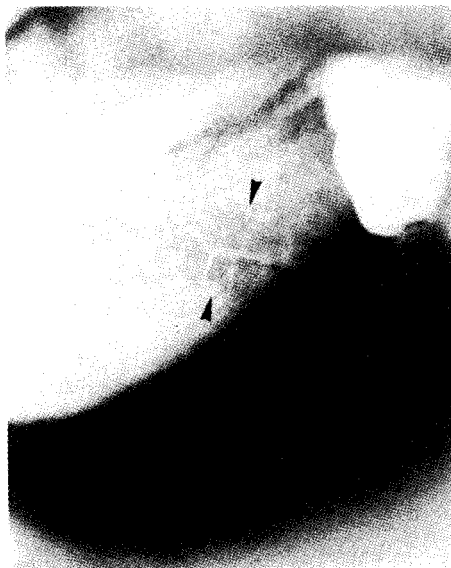

Fig. 2a. Buccal mucosa involvement.

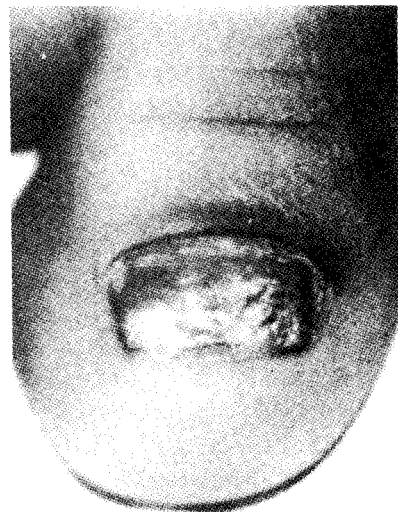

Fig. 2b. Nail abnormalities.

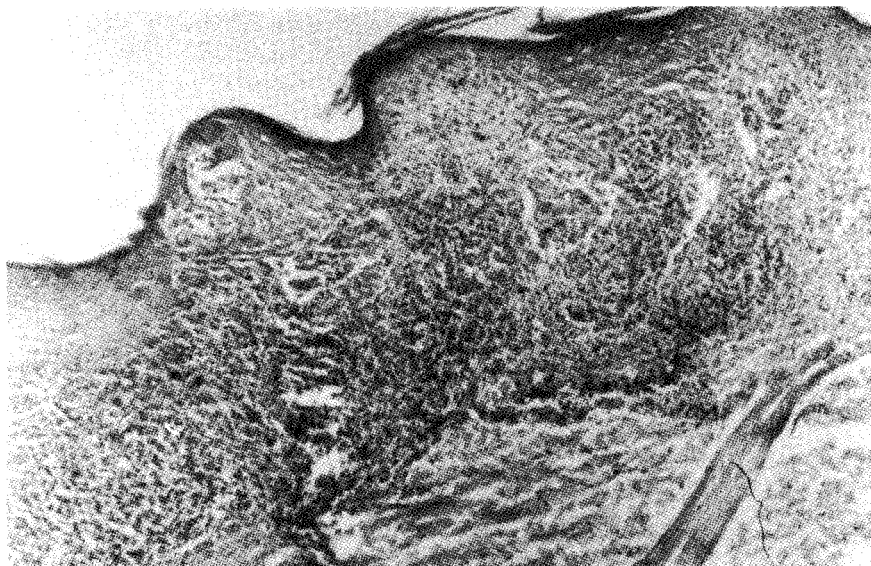


Fig. 3. Lichenoid infiltration, irregular rete ridges of epidermis and focal hypergranulosis (H&E, x40).

## Discussion

The incidence of classic LP lesions with violaceous, polygonal, flat-topped papules has been reported to occur in childhood cases by Kanwar<sup>2</sup> and Kumar et al.<sup>6</sup> at rates of 76% and 56% respectively. In contrast, Milligan et al.<sup>3</sup> experienced only one classical case out of six presenting with childhood LP. Our case was a classical generalized LP with prominent Köbner's phenomenon.

Oral LP is rare in children. Very few of the children with cutaneous lesions were reported to have oral LP simultaneously. Of 17 patients, only one had violaceous lesions over the lips in Kanwar's series<sup>2</sup>. In the study of Kumar et al.<sup>6</sup>, oral mucosal involvement with 20-nail dystrophy was detected in only one patient among 25 children. Three girls, having buccal and/or lingual mucosal LP without skin involvement were reported. Two of them were manifested with erosive lesions and one was in reticulopapular pattern<sup>7</sup>.

Lichen planus (LP) of the nails in children has been rarely described<sup>2,8</sup>. Nail abnormalities characterized by longitudinal ridging, pterygium and scarring atrophic dystrophy were reported in four children by Colver et al.<sup>9</sup>; longitudinal ridging and onycholysis were described by Peluso et al.<sup>10</sup> in the absence of skin or mucous membrane lesions. Twenty-nail dystrophy of childhood due to LP was also reported<sup>11</sup>. However, in the series of Milligan et al.<sup>3</sup>, only one patient was described to have skin lesions associated with nail changes. To our knowledge, our case was different than the previous reports with diffuse skin involvement accompanied by oral mucosal and nail lesions. However, a nail matrix biopsy would have been helpful to confirm the nail involvement.

Therapeutical approach consists of systemic antihistamines and corticosteroids<sup>1-3,10</sup>, acitretin<sup>5</sup>, dapsone<sup>6</sup> and griseofulvin<sup>5</sup> for extensive involvement. Considering the adverse effects of oral steroids and the risk of premature epiphyseal closure due to acitretin in children, dapsone was preferred in this case.

Lichen planus (LP) may follow a prolonged time-course in children, and there are some variants resistant to conservative therapies<sup>3,5</sup>. Although it was reported that 94% of cases cleared in less than a year as in adults<sup>2</sup>, we had to continue the treatment up to one year, increasing the dosage because of the progression of the lesions. We observed difficulty in controlling the lesions particularly on the lower extremities. Oral mucosal lesions were cleared and nail changes were slightly improved with dapsone therapy. In addition, no adverse effects were detected. We concluded that dapsone may be an alternative treatment modality, especially to alleviate pruritus, and that it is safe as well, even in long-term use. However, treatment of a series of patients or blinded and controlled studies would be necessary to prove that this treatment modality for childhood lichen planus is safe and effective.

## REFERENCES

1. Brice SL, Barr RJ, Rattet JP. Childhood lichen planus-a question of therapy. *J Am Acad Dermatol* 1980; 3: 370-376.
2. Kanwar AJ, Handa S, Ghoush S, Kaur S. Lichen planus in childhood: a report of 17 patients. *Pediatr Dermatol* 1991; 8: 288-291.
3. Milligan A, Graham-Brown RA. Lichen planus in children-a review of six cases. *Clin Exp Dermatol* 1990; 15: 340-342.
4. de Berker D, Dawber R. Childhood lichen planus. *Clin Exp Dermatol* 1991; 16: 233.
5. Howard R, Tsuchiya A. Adult skin disease in the pediatric patient. *Dermatol Clin* 1998; 16: 593-608.
6. Kumar V, Garg BR, Baruah MC, Vasireddi SS. Childhood lichen planus. *J Dermatol* 1993; 20: 175-177.
7. Scully C, de Almedia OP, Welbury R. Oral lichen planus in childhood. *Br J Dermatol* 1994; 130: 131-133.
8. Boyd AS, Neldner KH. Lichen planus. *J Am Acad Dermatol* 1991; 25: 593-619.
9. Colver GB, Dawber RP. Is childhood idiopathic atrophy of the nails due to lichen planus? *Br J Dermatol* 1987; 116: 709-712.
10. Peluso AM, Tosti A, Piraccini BM, Cameli N. Lichen planus limited to the nails in childhood: case report and literature review. *Pediatr Dermatol* 1993; 10: 36-39.
11. Wilkinson JD, Dawber RP, Bowers RP, Fleming K. Twenty-nail dystrophy of childhood. Case report and histopathological findings. *Br J Dermatol* 1979; 100: 217-221.