

# Diastolic forward blood flow in the pulmonary arteries of normal children: a Doppler echocardiographic study

Ayşe Güler Eroğlu, Ayşe Sarıoğlu

Department of Pediatric Cardiology, İstanbul University Institute of Cardiology, İstanbul, Turkey

**SUMMARY:** Eroğlu AG, Sarıoğlu A. Diastolic forward blood flow in the pulmonary arteries of normal children: a Doppler echocardiographic study. *Turk J Pediatr* 2001; 43: 52-54.

Pulmonary arterial flow was examined in 60 normal children with a mean age of  $8.5 \pm 3.7$  years (range 3.3 to 17.9 years) and mean body surface area of  $0.95 \pm 0.3$  m<sup>2</sup> (range 0.6 m<sup>2</sup> to 1.7 m<sup>2</sup>) by pulsed Doppler echocardiography. Two distinct antegrade waveforms during diastole were detected. The peak velocities of early diastolic forward flow ranged from 20 to 30 cm/s (mean  $26 \pm 4$ ) and the late diastolic forward flow ranged from 16 to 29 cm/s (mean  $23 \pm 3$ ). The integrals of early diastolic forward flow ranged from 2.1 to 4.7 cm (mean  $3.1 \pm 0.7$ ) and late diastolic forward flow ranged from 1 to 3.6 cm (mean  $2.1 \pm 0.7$ ). Duration of early diastolic forward flow ranged from 161 to 256 ms (mean  $187 \pm 29$ ) and late diastolic forward flow ranged from 82 to 188 ms (mean  $133 \pm 29$ ). Data analysis for age indicated no significant difference in these measurements between children three to nine years old ( $n = 33$ ) and children 9.1 to 18 years old ( $n = 27$ ). The effect of respiration was observed in 10 randomly chosen subjects (mean age  $8.6 \pm 4.1$  years). Although early and late diastolic peak forward flow velocities, flow velocity integrals and flow duration during inspiration tended to be larger than during expiration, only late diastolic peak forward flow velocities during inspiration were significantly larger than during expiration ( $24.2 \pm 3.2$  versus  $18.2 \pm 3$  cm/s,  $p = 0.001$ ). This study defines normal Doppler ultrasound pulmonary arterial flow velocities, flow velocity integrals and flow duration during diastole in normal children. These results can be used for comparison with patterns found in disease states.

**Key words:** echocardiography, pulmonary artery, diastolic function.

Several recent reports have suggested that late diastolic forward flow in the pulmonary artery throughout the respiratory cycle could be of diagnostic value in children with restrictive right ventricular physiology<sup>1-6</sup>. In this study, we examined the normal patterns of pulmonary blood flow and provide quantitative normal values for the major waveforms seen during diastole in normal children.

## Material and Methods

This study group consisted of 60 normal children with a mean age of  $8.5 \pm 3.7$  years (range 3.3 to 17.9 years) and mean body surface area of  $0.95 \pm 0.3$  m<sup>2</sup> (range 0.6 m<sup>2</sup> to 1.7 m<sup>2</sup>). They had normal physical and echocardiographic examinations. Transthoracic echocardiography was performed with 4 MHz transducer

interfaced with an Acuson 128/XP 10 ultrasound system. Measurements were made with simultaneous recording of the electrocardiogram. Spectral recordings were made, with minimal filtering, on paper at a speed of 100 cm/s. After the diagnostic imaging pulsed Doppler recordings were made with the subject in the lateral decubitus position. Pulmonary arterial flow was determined by placing the pulsed Doppler sample at the midpoint between the pulmonary valvar leaflets and the bifurcation of the pulmonary trunk in short axis at the left parasternal edge. Peak velocities, velocity integrals and duration of forward flow in systole, early diastole and late diastole were measured. All time intervals were corrected by the RR intervals on the electrocardiogram as follows: corrected time interval = time interval/ $\sqrt{RR}$ . Six cardiac cycles

were analyzed, and the results for each index averaged to minimize the effects of respiration. Data are expressed as mean  $\pm$  SD. Student's t test was used to compare normally distributed variables; otherwise, a Mann-Whitney U test was performed. Statistical significance was inferred at a value of  $p < 0.05$ .

## Results

All 60 subjects had tracing adequate for analysis. The spectral display of pulmonary arterial blood flow obtained by pulsed Doppler echocardiography had three distinct waveforms during each cardiac cycle. The initial waveform was antegrade waveforms during systole. Two distinct antegrade waveform during diastole were detected, the first occurring in early diastole and the second in late diastole. Figure 1 shows the pulsed Doppler recording from the pulmonary artery of a normal child. Table I displays the mean values and the ranges of peak flow velocities, flow velocity integrals and duration of antegrade flow during

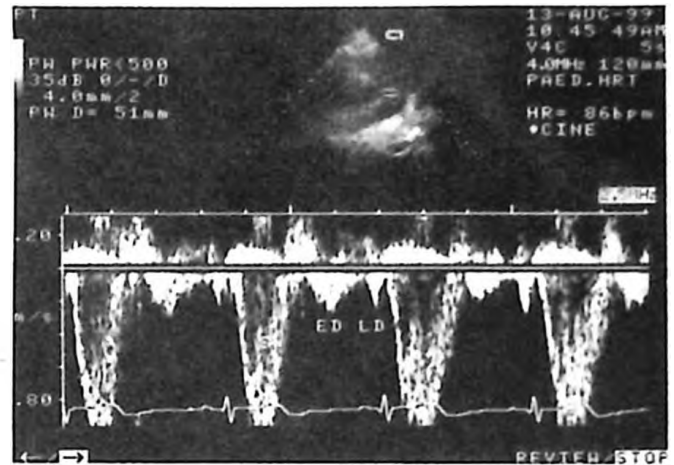


Fig. 1. Pulsed-Doppler recording from the pulmonary artery of a normal child. S = systolic flow; ED: early diastolic flow; LD = late diastolic flow.

$133 \pm 29$ ). Two subgroups were defined to assess the effects of age. The 60 children were categorized by age: three to nine years ( $n = 33$ ) and 9.1 to 18 years ( $n = 27$ ). Data analysis for age indicated no significant difference in peak forward flow

Table I. Pulmonary Arterial Forward Flow Velocity, Flow Velocity Integral and Flow Duration During Systole, Early Diastole and Late Diastole in 60 Normal Children

Parameter	Mean $\pm$ SD	Range
Systolic forward flow velocity, cm/s	104 $\pm$ 16	82-128
Systolic forward flow integral, cm	21 $\pm$ 3	16-28
Systolic forward flow duration, ms	369 $\pm$ 34	307-474
Early diastolic forward flow velocity, cm/s	26 $\pm$ 4	20-30
Early diastolic forward flow integral, cm	3.1 $\pm$ 0.7	2.1-4.7
Early diastolic forward flow duration, ms	187 $\pm$ 29	161-256
Late diastolic forward flow velocity, cm/s	23 $\pm$ 3	16-29
Late diastolic forward flow integral, cm	2.1 $\pm$ 0.7	1-3.6
Late diastolic forward flow duration, ms	133 $\pm$ 29	82-188

systole, early diastole and late diastole. In the 60 normal children, the peak velocities of early diastolic forward flow ranged from 20 to 30 cm/s (mean  $26 \pm 4$ ) and the late diastolic forward flow ranged from 16 to 29 cm/s (mean  $23 \pm 3$ ). The integrals of early diastolic forward flow ranged from 2.1 to 4.7 cm (mean  $3.1 \pm 0.7$ ) and late diastolic forward flow ranged from 1 to 3.6 cm (mean  $2.1 \pm 0.7$ ). Duration of early diastolic forward flow ranged from 161 to 256 ms (mean  $187 \pm 29$ ) and late diastolic forward flow ranged from 82 to 188 ms (mean

velocities, flow velocity integrals and flow duration during systole, early diastole and late diastole between children three to nine years old and children 9.1 to 18 years old. The effect of respiration was observed in 10 randomly chosen subjects (mean age  $8.6 \pm 4.1$  years). Although early and late diastolic peak forward flow velocities, flow velocity integrals and flow duration during inspiration tended to be larger than during expiration, only late diastolic peak forward flow velocities during inspiration were significantly larger than during expiration ( $24.2 \pm 3.2$  versus  $18.2 \pm 3$  cm/s,  $p=0.001$ ) (Table II).

Table II. Effect of Respiratory Phase on Diastolic Pulmonary Arterial Forward Flows in 10 Normal Children

Parameter	Inspiration	Expiration	p
Early diastolic forward flow velocity, cm/s	25±3	23±4	0.24
Early diastolic forward flow integral, cm	3.1±1	2.4±0.5	0.12
Early diastolic forward flow duration, ms	191±29	170±22	0.11
Late diastolic forward flow velocity, cm/s	24±3	18±3	0.001*
Late diastolic forward flow integral, cm	2±0.5	1.5±0.5	0.10
Late diastolic forward flow duration, ms	143±26	129±27	0.31

## Discussion

Recently, pulmonary arterial forward flow patterns during late diastole have been reported as a sensitive mean of recognizing right heart filling abnormalities noninvasively<sup>1-6</sup>. It has been proposed that increased late diastolic forward flow in the pulmonary artery reflects reduced right ventricular diastolic compliance, suggesting that the right ventricle is unfillable and truly restrictive at end diastole, so acting as a passive conduit between the right atrium and pulmonary artery during atrial systole<sup>1</sup>. Less cardiomegaly and improved exercise performance have been demonstrated in patients with restrictive right ventricular physiology after tetralogy of Fallot repair at long-term follow-up<sup>2</sup>. We have recently demonstrated that increased late diastolic forward flow (> 30 cm/s) in the pulmonary arteries of patients with tetralogy of Fallot at mid-term follow-up, subsequent to repair using a transannular patch, is associated with smaller right ventricular size and less prolongation of QRS complex. The purpose of this study was to establish normal values for pulmonary arterial diastolic forward flow velocities, flow velocity integrals and flow duration in normal children for future comparison with values obtained in cardiac diseases. As previously reported<sup>7</sup>, there are two distinct forward flow waveforms in pulmonary arteries of normal subjects during diastole. Gibbs et al.<sup>7</sup> reported pulmonary arterial forward flow velocities during early and late diastole in 50 normal infants and adults aged two months to 42 years (mean 14.3 years), using pulsed wave Doppler recordings, that were smaller than those observed in our normal children. In their study, peak early diastolic forward flow velocities ranged from 15 to 30 cm/s (mean 21) and peak late diastolic forward flow velocities ranged from 20 to 30 cm/s (mean 25). The difference may be due to age difference between the two study subjects. Their study population included normal adults in addition to normal children and their mean age was greater than ours.

The 60 children were divided into a younger and an older group, and no differences were found

between these two groups in forward flow velocities, flow velocity integrals or flow duration during early diastole and late diastole. The present study indicates that age has no influence on diastolic forward flow measurements in pulmonary arteries of normal children.

The effect of respiration was examined. Although early and late diastolic peak forward flow velocities, flow velocity integrals and flow duration during inspiration tended to be larger than during expiration, only late diastolic peak forward flow velocities reached statistical significance.

This study defines normal Doppler ultrasound pulmonary arterial flow velocities, flow velocity integrals and flow duration during diastole in normal children. These results can be used for comparison with patterns found in disease states.

## REFERENCES

1. Redington AN, Penny D, Rigby ML, Hayes A. Antegrade diastolic pulmonary arterial flow as a marker of right ventricular restriction after complete repair of pulmonary atresia with intact septum and critical pulmonary valvar stenosis. *Cardiol Young* 1992; 2: 382-386.
2. Gatzoulis MA, Clark AL, Cullen S, Newman CG, Redington AN. Right ventricular diastolic function 15 to 35 years after repair of tetralogy of Fallot: restrictive physiology predicts superior exercise performance. *Circulation* 1995; 91: 1775-1781.
3. Cullen S, Shore D, Redington A. Characterization of right ventricular diastolic performance after complete repair of tetralogy of Fallot: restrictive physiology predicts slow postoperative recovery. *Circulation* 1995; 91: 1782-1789.
4. Norgard G, Gatzoulis MA, Moraes F, et al. Relationship between type of outflow tract repair and postoperative right ventricular diastolic physiology in tetralogy of Fallot: implications for long-term outcome. *Circulation* 1996; 94: 3276-3280.
5. Helbing WA, Niezen RA, le Cessie S, van der Geest RJ, Ottenkamp J, de Roos A. Right ventricular diastolic function in children with pulmonary regurgitation after repair of tetralogy of Fallot: volumetric evaluation by magnetic resonance velocity mapping. *J Am Coll Cardiol* 1996; 28: 1827-1835.
6. Eroglu AG, Sarioglu A, Sarioglu T. Right ventricular diastolic function after repair of tetralogy of Fallot: its relationship to the insertion of a 'transannular patch'. *Cardiol Young* 1999; 9: 384-391.
7. Gibbs JL, Wilson N, Witsenburg M, Williams GJ, Goldberg SJ. Diastolic forward flow in the pulmonary artery detected by Doppler echocardiography. *J Am Coll Cardiol* 1985; 6: 1322-1328.