

## RESPIRATORY DISTRESS DUE TO ESOPHAGEAL PERFORATION CAUSED BY BALL POINT INGESTION\*

Aydın Türken MD\*\*, F. Cahit Tanyel MD\*\*\*, Akgün Hiçsönmez MD\*\*\*

**SUMMARY:** Türken A, Tanyel FC, Hiçsönmez A. (Department of Pediatric Surgery, Hacettepe University Faculty of Medicine, Ankara, Turkey). Respiratory distress due to esophageal perforation caused by ball point ingestion. Turk J Pediatr 1999; 41: 391-393.

A 15-month-old girl who developed respiratory distress which persisted for three days prior to admission demonstrated pleural effusion on the chest x-ray which was determined to be due to esophageal perforation caused by the ingestion of a ball point. A gastrotomy was performed to extract the ball point. A gastrostomy was performed and a chest tube was inserted. The esophagus was normal radiologically within one month. Foreign body ingestion may cause esophageal perforation in childhood. If it goes unnoticed and a diagnosis is delayed, there is danger of the more hazardous development of mediastinitis. It is important that a child with respiratory distress also be evaluated for esophageal foreign body ingestion.

*Key words:* esophageal perforation, respiratory distress.

Respiratory distress is a frequent cause of emergency admission of young children<sup>1</sup>. Among the numerous causes of respiratory distress, esophageal perforation resulting from unwitnessed foreign body ingestion accounts for a small percentage. Although foreign body perforation of the esophagus has a favorable prognosis, a delay in diagnosis and treatment can lead to a fatal outcome<sup>2-3</sup>.

A 15-month-old infant who was in respiratory distress due to esophageal perforation is presented to stress the possibility of esophageal perforation as a cause of respiratory distress in childhood.

### Case Report

A 15-month-old girl was admitted with respiratory distress. Her complaints had begun three days prior to admission with coughing and vomiting. The characteristics of the vomitus had changed from the ingesta to bilious, and respiratory distress had become the predominant symptom.

On physical examination, tachypnea together with substernal, suprasternal and intercostal retractions were observed. Her pulse rate was 120/min, blood pressure 100/70 mmHg and axillary temperature was 38.2 °C. Auscultation revealed absence of respiratory sounds on the right hemithorax. A pencil-like substance of 6 cm was palpated in the epigastric area beneath the xyphoid directed to the umbilicus. When this was brought to the attention of the parents, they recalled seeing the baby playing with a ball point three days previously.

---

\* From the Department of Pediatric Surgery, Hacettepe University Faculty of Medicine, Ankara.

\*\* Research Assistant in Pediatric Surgery, Hacettepe University Faculty of Medicine.

\*\*\* Professor of Pediatric Surgery, Hacettepe University Faculty of Medicine.

Routine investigations including complete blood count, urinalysis and biochemistry were in normal limits. Chest x-rays obtained in posteroanterior and lateral directions revealed pleural effusion in the right hemithorax, and the radiopaque tip of the ball point at the level of the 5<sup>th</sup> thoracic vertebra (Figs. 1-2).

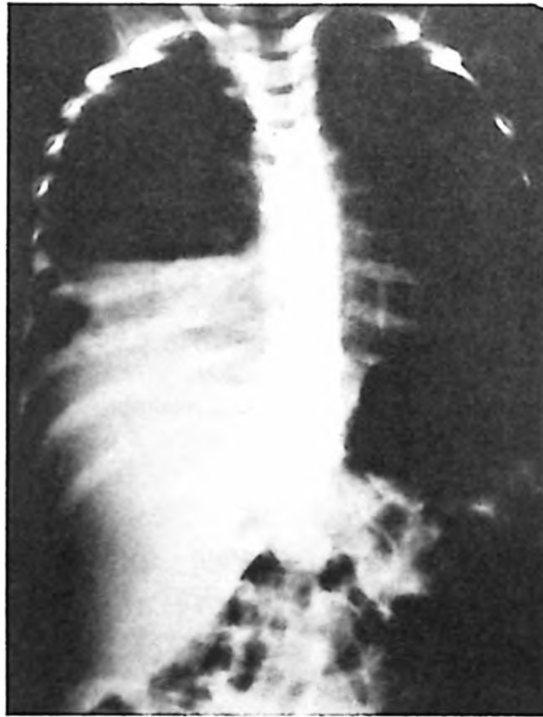


Fig. 1: Posteroanterior projection showing pleural effusion and the radiopaque tip of the ball point.

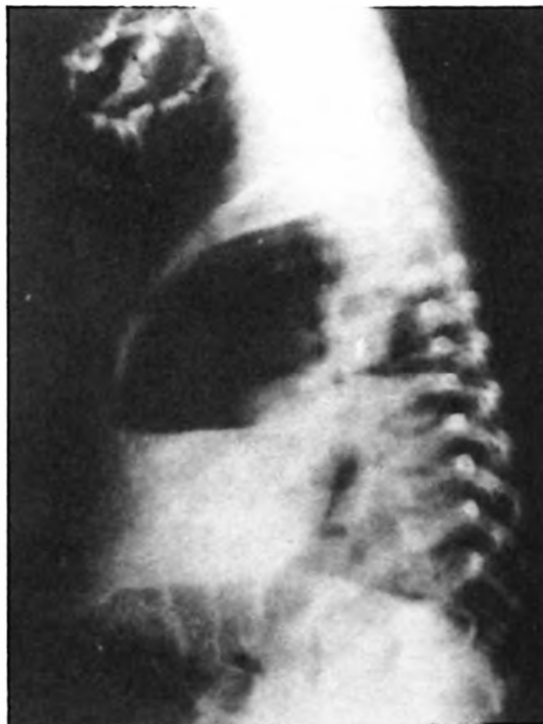


Fig. 2: Lateral projection showing the same findings.

Following initial resuscitation she was taken into the operating room with the diagnosis of esophageal perforation from ball point ingestion. Initial attempts of esophagoscopy removal unfortunately failed. Due to cranial direction of the perforating tip, removal by gastrotomy was decided. Through a midline laparotomy and gastrotomy the ball point was easily extracted. A Stamm gastrostomy was performed through the same incision. A chest tube was inserted through the right 6<sup>th</sup> intercostal space for underwater drainage and remained until the drainage ceased. Feeding through the gastrostomy was initiated afterwards.

The esophagogram was normal one month after operation. The patient has been free of symptoms and findings for two years.

## Discussion

Foreign body ingestion is a frequent reason for emergency admission of young children around the world<sup>1</sup>. Seven to 14 percent of ingestions result in esophageal perforations, with the intrathoracic portion the most common site of involvement<sup>2-3</sup>.

The most common symptoms of esophageal perforation are refusal to take foods, increased salivation, pain on swallowing and vomiting<sup>4</sup>.

Radiological findings of esophageal perforations are dependent upon the time interval between perforation and radiological examination, site of perforation and integrity of mediastinal pleura<sup>5</sup>. If the ingestion is unwitnessed and symptoms unrelated to the esophagus predominate, consideration of a diagnosis of esophageal perforation becomes more difficult. Respiratory distress, without any complaints related to swallowing initially directed us toward the common causes of respiratory distress among infants. Palpation of a pencil-like object led to careful examination of the chest x-rays which revealed the radiopaque tip of the ball point with pleural effusion on the right hemithorax, making the diagnosis of esophageal perforation easy.

Foreign body perforation of the esophagus usually has a favorable outcome; however, it depends on the time interval between injury and initiation of the treatment. A delay in diagnosis worsens the outcome<sup>2-3</sup>.

In conclusion, esophageal perforation complicating unwitnessed foreign body ingestion should be considered in the differential diagnosis among infants with respiratory distress, even in the absence of signs and symptoms related to swallowing.

## REFERENCES

1. American Medical Association Commission on Emergency Medical Services: Pediatric emergencies. *Pediatrics* 1990; 85: 879-887.
2. Jones WG, Ginsberg RJ. Esophageal perforation: a continuing challenge. *Ann Thorac Surg* 1989; 53: 534-543.
3. Bladergroen MR, Lowe JE, Postlethwaite RW. Diagnosis and recommended management of esophageal perforation and rupture. *Ann Thorac Surg* 1986; 42: 235-239.
4. Nandi P, Ong GB. Foreign body in the esophagus: review of 2394 cases. *Br J Surg* 1978; 65: 5-9.
5. DeMeester T. Perforation of the esophagus. *Ann Thorac Surg* 1986; 42: 231-232.