

# Extracorporeal carbon dioxide removal for acute hypercapnic respiratory failure in a child with cystic fibrosis

Gökçen Özçifçi<sup>1</sup>, Gülizar Koç<sup>1</sup>, Eda Eydurhan<sup>2</sup>, Fatih Durak<sup>3</sup>, Ayşe Berna Anıl<sup>3</sup>

<sup>1</sup>Department of Pediatric Intensive Care Unit, University of Health Sciences Tepecik Training and Research Hospital, İzmir;

<sup>2</sup>Department of Pediatrics, University of Health Sciences Tepecik Training and Research Hospital, İzmir; <sup>3</sup>Department of Pediatric Intensive Care Unit, İzmir Katip Celebi University Medical Faculty, İzmir, Türkiye.

## ABSTRACT

**Background.** Acute respiratory failure is a prevalent condition in childhood with a high rate of mortality. Invasive mechanical ventilation support may be required for the management of these patients. Extracorporeal membrane oxygenation (ECMO) is a method used when ventilation support is insufficient. However, the less invasive extracorporeal carbon dioxide removal method can be used as an alternative in cases of hypercapnic respiratory failure.

**Case.** A 9-year-old patient with cystic fibrosis presented to the hospital with acute respiratory failure due to pneumonia. Bilateral patchy areas of consolidation were evident in the chest x-ray. Invasive mechanical ventilation support was consequently provided to treat severe hypercapnia. Although peak and plateau pressure levels exceeded 32 cmH<sub>2</sub>O (49 cmH<sub>2</sub>O) and 28 cmH<sub>2</sub>O (35 cmH<sub>2</sub>O), respectively, the patient continued to have severe respiratory acidosis. Therefore extracorporeal carbon dioxide removal support was initiated to provide lung-protective ventilation. By Day 10, venovenous ECMO support was initiated due to deteriorating oxygenation.

**Conclusion.** In cases where conventional invasive mechanical ventilation support is insufficient due to acute hypercapnic respiratory failure, extracorporeal carbon dioxide removal support, which is less invasive compared to ECMO, should be considered as an effective and reliable alternative method. However, it should be noted that extracorporeal carbon dioxide removal support does not affect oxygenation; it functions solely as a carbon dioxide removal system.

**Key words:** extracorporeal carbon dioxide removal, extracorporeal membrane oxygenation (ECMO), hypercapnic respiratory failure, pediatric intensive care unit.

Acute respiratory failure (ARF) is the ineffective oxygenation, ventilation, or both in the respiratory system. The extracorporeal carbon dioxide removal (ECCO<sub>2</sub>R) technique assists in the improvement of hypercapnia and respiratory acidosis by the removing of CO<sub>2</sub> from the blood.<sup>1</sup> This method is similar to extracorporeal membrane oxygenation (ECMO); however, it uses lower blood flow rates. Therefore, ECCO<sub>2</sub>R

can be administered more readily and requires smaller venous access. In contrast, it has little or no effect on blood oxygenation.<sup>2</sup>

ECCO<sub>2</sub>R can be used to implement a lung-protective strategy in acute respiratory distress syndrome (ARDS), during weaning off mechanical ventilation in chronic obstructive pulmonary disease (COPD), and reduce the need for invasive mechanical ventilation (IMV) in hypercapnic respiratory failure.<sup>3,4</sup> This technique is more commonly used in adults, and there is no available literature on the use of ECCO<sub>2</sub>R in the pediatric age group in our country. The purpose of the present study is

✉ Gökçen Özçifçi  
gknozcfici@gmail.com

Received 3rd Jul 2023, revised 7th Nov 2023, 8th Dec 2023,  
10th Jan 2024, 25th Feb 2024, accepted 24st Apr 2024.

to share the experience of using ECCO<sub>2</sub>R in a pediatric patient with cystic fibrosis, who had acute hypercapnic respiratory failure.

### Case

A 9-year-old girl with cystic fibrosis was admitted to the hospital due to the sudden onset of respiratory distress. She had a history of neonatal surgery for ileal atresia and had been admitted to the pediatric intensive care unit (PICU) multiple times for recurrent pneumonia. It was established that she had not received chronic respiratory support prior to this, but had not presented to the hospital for regular check-ups for over a year. Therefore, her baseline condition was not clearly known.

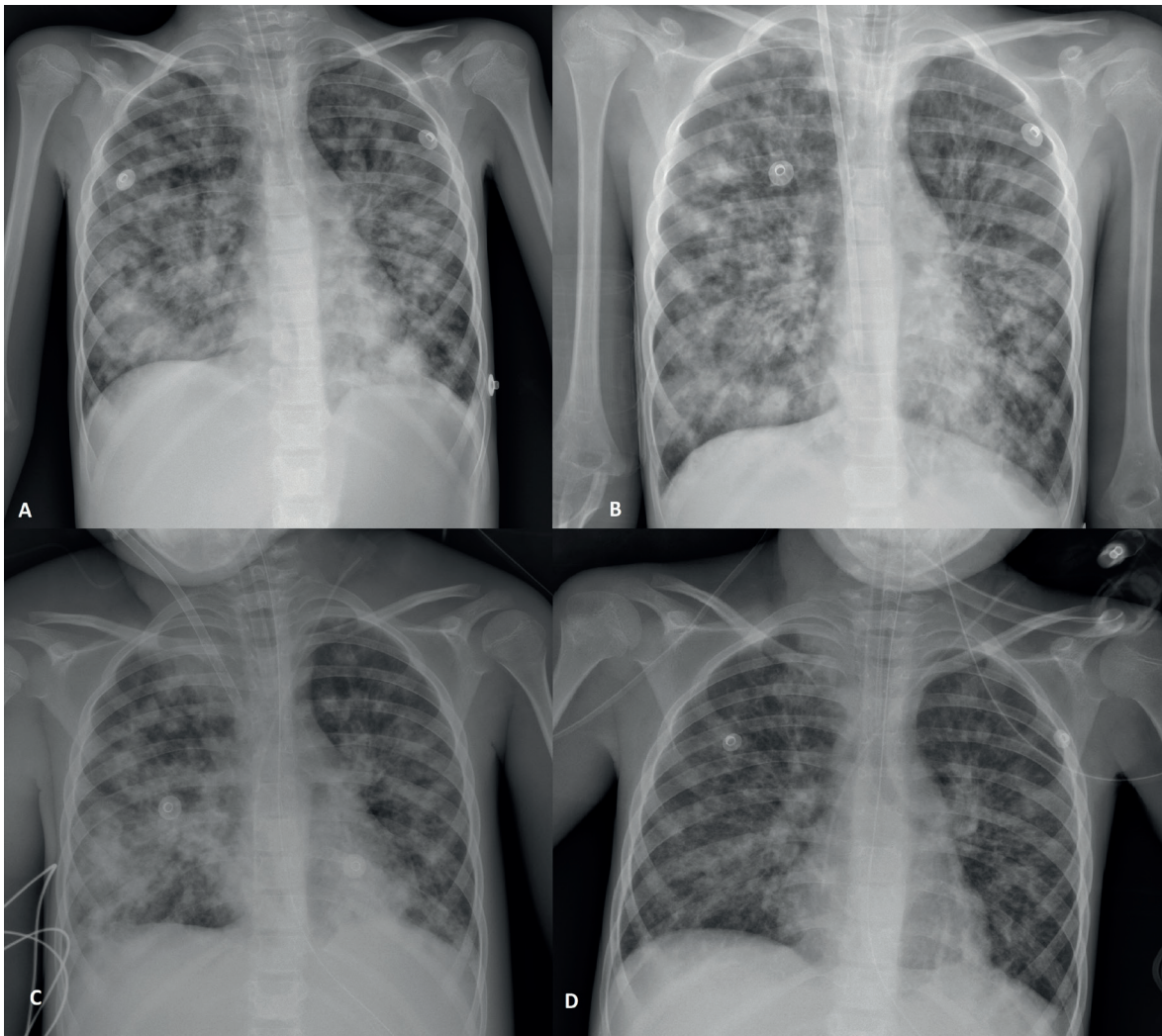
According to the physical examination, her general condition was poor, but she remained conscious. Her heart rate was 160/minute, blood pressure was 122/83 mmHg, respiratory rate was 52/minute, oxygen saturation was 74% at room temperature and 96% with a reservoir mask. Capillary refill time was 2 seconds. She weighed 18 kg. She had subcostal and intercostal retractions, and bilateral ronchi and crepitant rales were audible on auscultation. A chest x-ray revealed bilateral patchy areas of consolidation (Fig. 1).

Additional physiological tests yielded the following results: blood gas pH 7.27, pCO<sub>2</sub> 79.4 mmHg, HCO<sub>3</sub> 30 mmol/L, lactate 3.1 mmol/L, base deficit 8.9, hemoglobin (measured via complete blood count) 10 g/dL, hematocrit 31.7%, platelets 608000/mm<sup>3</sup>, leukocyte count 20900/mm<sup>3</sup>, blood glucose (biochemical examination) 158 mg/dL, aspartate aminotransferase 91 U/L, alanine aminotransferase 43 U/L, C-reactive protein 232.4 mg/L, procalcitonin 36.8 ng/mL, and albumin 2.3 g/L. Other blood parameters were within normal ranges.

She received oxygen support via a high-flow nasal cannula. Treatments included dornase alfa, salbutamol, and 3% NaCl nebulae, along with an intravenous dose of 50 mg/kg of magnesium sulfate. Blood and urine cultures

were collected, and the patient was started on teicoplanin (10 mg/kg/day), meropenem (120 mg/kg/day), and amikacin (30 mg/kg/day). Due to severe hypercapnic respiratory failure (pH: 7.06, pCO<sub>2</sub>: 120 mmHg, HCO<sub>3</sub>: 23.5 mmol/L, lactate: 1.3 mmol/L, base deficit: 3), the patient was intubated using a 5.0 cuffed tube with a rapid sequential intubation protocol and connected to a mechanical ventilator. She was monitored in adaptive pressure ventilation synchronised intermittent mandatory ventilation mode with a tidal volume target (V<sub>T</sub>) of 140 mL (7.8 mL/kg), positive end-expiratory pressure (PEEP) of 6 cmH<sub>2</sub>O, fraction of inspired oxygen (FiO<sub>2</sub>) of 60%, frequency of 25/min, inspiratory time of 0.6 seconds, and peak inspiratory pressure (P<sub>peak</sub>) of 46 cmH<sub>2</sub>O. Right femoral central venous catheter, right radial artery catheter, and urinary catheter were inserted. Midazolam (0.2 mg/kg/h) and fentanyl (1 mcg/kg/h) infusions were started for sedation and analgesia, with rocuronium (0.4 mg/kg/h) used for paralysis. A tracheal aspirate culture was sent for further examination. Caspofungin treatment was initiated for allergic bronchopulmonary aspergillosis. Total immunoglobulin E and immunoglobulin E levels specific to *Aspergillus fumigatus* were normal.

During follow-up, persistent severe respiratory acidosis was observed (pH: 7.11, pCO<sub>2</sub>: 102.3 mmHg, HCO<sub>3</sub>: 23.9 mmol/L, lactate: 2.7 mmol/L, base deficit: 3.2). ECCO<sub>2</sub>R was planned due to peak and plateau pressure levels exceeding 32 cmH<sub>2</sub>O (49 cmH<sub>2</sub>O) and 28 cmH<sub>2</sub>O (35 cmH<sub>2</sub>O), respectively (Fig. 2). Additionally, a 12F hemodialysis catheter was inserted through the right internal jugular vein, and ECCO<sub>2</sub>R treatment was initiated (PrismaLung, Baxter Healthcare/ Gambro, Lund, Sweden, allowing for a blood flow rate ranging from 80 to 450 mL/min in a patient weighing 18 kg, with a surface area of 0.35 m<sup>2</sup>). Initial settings included a gas flow rate of 2 L/min, blood flow rate of 100 mL/min, and heparin infusion rate of 10 U/kg/h. Gas flow rate and blood flow rate were adjusted according to the treatment target, while heparinization was regulated based on

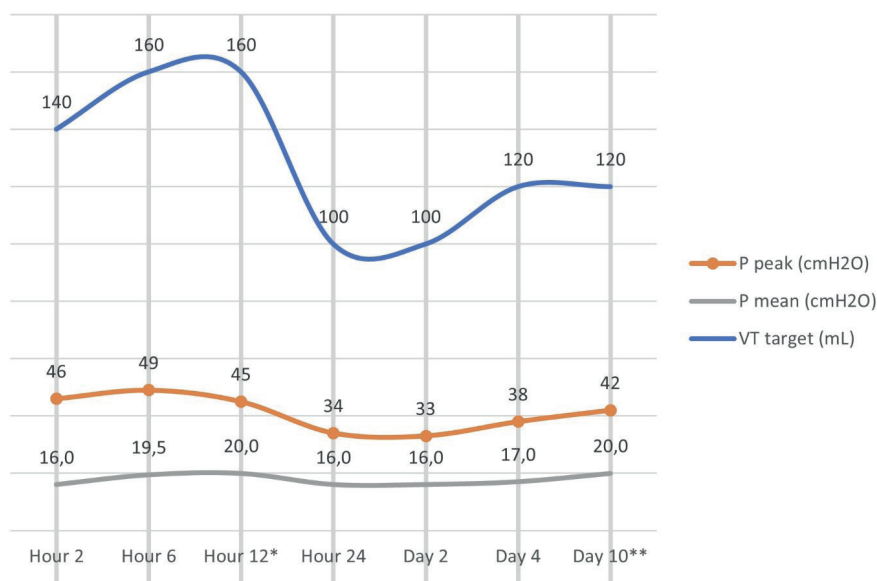


**Fig. 1.** Chest X-ray images of the patient.

**A,** Patchy-like bilateral infiltrative consolidation areas at the patient's admission; **B,** Similar ongoing consolidation areas while the patient is being placed on ECCO<sub>2</sub>R support, **C,** Increased consolidation areas on the patient's chest radiograph taken when ECMO support was started, and **D,** Chest radiograph showing the patient's recovery trend when weaned from ECMO support. ECCO<sub>2</sub>R: extracorporeal carbon dioxide removal, ECMO: extracorporeal membrane oxygenation.

the activated clotting time (ACT) and activated partial thromboplastin time (aPTT) target. In ECCO<sub>2</sub>R support, we applied the following treatment targets: respiratory rate < 25/min,  $V_T \leq 6$  mL/kg for ventilatory settings, and pH > 7.30, and PaCO<sub>2</sub> < 55 mmHg for blood gas values. We maintained the ACT and aPTT targets within the ranges of 180–220 seconds and 60–80 seconds, respectively, according to the heparinization protocols. Lung-protective ventilation was performed using a mechanical ventilator with the following settings:  $V_T$ : 100

mL (5.5 mL/kg), frequency: 20/min, inspiratory time: 1 s, PEEP: 8 cmH<sub>2</sub>O, FiO<sub>2</sub>: 60%,  $P_{peak}$ : 30 cmH<sub>2</sub>O. One hour after initiating the ECCO<sub>2</sub>R procedure, blood gas values were as follows: pH 7.22, pCO<sub>2</sub> 72.3 mmHg, HCO<sub>3</sub> 24.9 mmol/L, lactate 2.2 mmol/L, PaO<sub>2</sub> 88 mmHg, and SpO<sub>2</sub> 96%. The targeted blood gas values (pH>7.30, pCO<sub>2</sub><55 mmHg) were ultimately achieved at 10 hours (Table I). ECCO<sub>2</sub>R settings were gas flow rate of 6 L/min and blood flow rate of 160 mL/min, when the target blood gas levels were reached. During the follow-up, gas flow was



**Fig. 2.** Ventilator settings during follow-up.

\* ECCO2R support was commenced here.

\*\* Switch to ECMO support here, VT: tidal volume.

**Table I.** Blood gas parameters, invasive mechanical ventilation and ECCO2R settings, and oxygenation parameters of the patient.

Parameters	Hour 0*	Hour 2*	Hour 6*	Hour 12 <sup>a</sup>	Hour 24	Day 2	Day 4	Day 10 <sup>b</sup>	
Blood gas parameters	pH	7.06	7.15	7.13	7.11	7.30	7.27	7.34	7.43
	pCO <sub>2</sub> , mmHg	120	85	97.4	102.3	55	58.2	65.3	54.4
	HCO <sub>3</sub> , mmol/L	23.5	23.4	24	23.9	24.1	23.7	32.1	34.8
	SpO <sub>2</sub> , %	43.6	68	60	52.5	92	88	93.3	90.7
	PaO <sub>2</sub> , mmHg	40.2	50	44	36.7	86	70	75.7	60.4
	Lactate, mmol/L	2.8	3.3	2.9	2.7	1.5	1.5	1.3	1.1
Mechanical ventilation settings	Frequency/min	X	25	25	25	20	20	20	22
	VT <sub>target</sub> , mL	X	140	160	160	100	100	120	120
	P <sub>peak</sub> , cmH <sub>2</sub> O	X	46	49	45	34	33	38	42
	P <sub>mean</sub> , cmH <sub>2</sub> O	X	16	19.5	20	16	16	17	20
	PEEP, cmH <sub>2</sub> O	X	6	7	8	8	8	8	10
	IT, seconds	X	0.6	0.7	0.8	1	1	0.9	0.9
	FiO <sub>2</sub> , %	X	60	60	60	70	70	65	70
ECCO <sub>2</sub> R settings	Blood flow velocity, mL/min	X	X	X	100	160	160	220	180
	Gas flow rate, L/min	X	X	X	2	4	6	10	2
Oxygenation index	X	10.1	12.7	15.6	15	16	14.5	23.2	

\* Oxygen saturation index was used because blood gas was venous.

<sup>a</sup> ECCO<sub>2</sub>R support was commenced here, <sup>b</sup> Switch to ECMO support here, ECCO<sub>2</sub>R: extracorporeal carbon dioxide removal, FiO<sub>2</sub>: fraction of inspired oxygen, IT: inspiratory time, PaO<sub>2</sub>: partial arterial pressure of oxygen, PEEP: positive end-expiratory pressure, Pmean: mean alveolar pressure, Ppeak: peak inspiratory pressure, SpO<sub>2</sub>: pulse oxygen saturation, VT: tidal volume.

increased by 10 L/min, and blood flow rate was increased by 220 mL/min to maintain the blood gas target. No ECCO<sub>2</sub>R-related complications were noted in the targeted CO<sub>2</sub> levels. A total of 4 filters were used. The first membrane change occurred within 24 hours due to membrane thrombosis.

An increase in oxygenation index, FiO<sub>2</sub>, and PEEP requirement was observed during follow-up. Due to problems related to oxygenation, the patient was switched from ECCO<sub>2</sub>R support to venovenous ECMO support by Day 10. *Pseudomonas aeruginosa* growth was identified in a tracheal aspirate culture. She responded positively to appropriate antibiotic therapy, based on the culture antibiogram, for the infection. This led to improvements in ventilation and oxygenation, and she was weaned off ECMO support on Day 29, but could not be weaned off IMV support during the follow-up; hence, tracheostomy was opened as a result of chronic respiratory failure and chronic ventilation support was continued.

The authors declare that they have obtained written consent from the family for the publication of this case report.

## Discussion

The annual incidence of PICU admission for ARF is 2.3%, with a mortality rate ranging from 24 to 34%. Although advancements in technology and IMV strategies have reduced mortality and morbidity in these patients, ARF remains a serious condition.<sup>5-8</sup> Currently, lung protective ventilation strategies are recommended in cases of respiratory failure requiring IMV support. Previous studies in the relevant literature have recommended the use of ECCO<sub>2</sub>R during acute and severe decompensation of COPD or to implement a lung-protective ventilation strategy in IMV for ARDS, especially in cases of hypercapnic respiratory failure.<sup>4,9</sup> The current patient was also diagnosed with cystic fibrosis and was admitted to the PICU with clinical manifestations of pneumonia, presenting a

more severe acute hypercapnic respiratory failure. Despite the patient's peak and plateau pressure levels exceeding 32 cmH<sub>2</sub>O and 28 cmH<sub>2</sub>O, respectively, ECCO<sub>2</sub>R support was initiated due to uncontrollable hypercapnia.

In our patient (age, 9 years; body weight, 18 kg), a 12 Fr temporary hemodialysis catheter was percutaneously inserted through the right internal jugular vein. Although typically not recommended for patients weighing less than 30 kg, the effective application of ECCO<sub>2</sub>R support in this patient was made possible by achieving appropriate and adequate venous access, ensuring sufficient blood flow rate. At the time ECCO<sub>2</sub>R was first introduced, arteriovenous 15 Fr and venovenous 18–19 Fr cannula sizes were required; however, in recent years, the system can be effectively used with smaller cannula sizes.<sup>10</sup> Data in the relevant literature regarding venovenous ECCO<sub>2</sub>R with percutaneously placed hemodialysis catheters in pediatric patients are limited. The most prevalent ECCO<sub>2</sub>R complication is bleeding and vascular injury, which can occur during the venous cannulation procedure.<sup>4</sup> Nevertheless, no complications related to venous access were observed in our patient.

A previous study reported a complete recovery from hypercapnia within 21–24 hours with ECCO<sub>2</sub>R support. However, this study focused on adult patients who received ECCO<sub>2</sub>R support via separate arterial and venous routes.<sup>11</sup> No specific studies have been conducted in the pediatric age group regarding this matter, and there is a lack of available data in the literature comparing the rate of CO<sub>2</sub> removal between single venous route and separate arterial and venous access. In our case, we utilized a single venous route for ECCO<sub>2</sub>R support, successfully achieving the targeted CO<sub>2</sub> levels within 10 hours.

A consensus study recommended treatment targets in ECCO<sub>2</sub>R support, including P<sub>plato</sub> <25 cmH<sub>2</sub>O, respiratory rate <25/min, V<sub>T</sub> ≤6 mL/kg, pH >7.30, and PaCO<sub>2</sub> <55 mmHg.<sup>12</sup> In our patient, ECCO<sub>2</sub>R support settings were gradually

increased to achieve these treatment goals. The desired targets were reached with a gas flow rate of 6 L/min and a blood flow rate of 160 mL/min. However, during the follow-up, the gas and blood flow rates were increased to 10 L/min and 220 mL/min, respectively, to maintain these targets.

Heparin is required for anticoagulation during ECCO<sub>2</sub>R administration, but clear targets for anticoagulation in pediatric patients are not well-defined.<sup>13</sup> In a case series study, heparin infusion doses ranged from 3 to 19 IU/minute, maintaining the ACT target between 150 and 200 seconds.<sup>14</sup> The consensus study recommended maintaining an aPTT target of 45–70 seconds or an anti Xa activity between 0.3 and 0.5 IU/mL, using an initial heparin bolus of 40–80 IU/kg, followed by infusion.<sup>12</sup> In our case, the heparinization protocol used in continuous renal replacement therapy was selected. After a 20 IU/kg heparin bolus dose, an infusion of 10 IU/kg/hour was initiated and adjusted to maintain the ACT and aPTT targets between 180–220 seconds and 60–80 seconds, respectively. Thrombocytopenia gradually developed from the patient's initial admission and persisted during the ECCO<sub>2</sub>R support. It is well-established that thrombocytopenia can result from the interaction of extracorporeal support systems with blood components and the transient effect of heparin infusion.<sup>13,15,16</sup> Hemorrhagic events are the most common complications during ECCO<sub>2</sub>R support, often requiring blood transfusions.<sup>4,11,17</sup> Despite the presence of thrombocytopenia in our patient, no bleeding complications occurred, and the heparinization procedure was sustained with blood product support.

Despite the use of anticoagulation protocols during ECCO<sub>2</sub>R support, clot formation in the circuit can occur. This situation can lead to a rapid increase in PaCO<sub>2</sub> especially in the patient. Membrane thrombosis should be considered a life-threatening condition, and circuit replacement should be promptly implemented.<sup>15,18</sup> In a retrospective study,

thrombosis was observed in 2 out of 3 patients receiving ECCO<sub>2</sub>R support with low blood flow rates in the circuit, while there was no thrombosis in 6 patients with high blood flow rates.<sup>19</sup> Another study reported that half of the patients with low blood flow experienced circuit thrombosis despite heparin anticoagulation.<sup>9</sup> In our case, ECCO<sub>2</sub>R support was initially provided at lower blood flow rates, yet circuit replacement was required during the early period (first 24 hours) due to membrane thrombosis. Subsequently, the recommended 72-hour membrane use period at higher blood flow rates was completed without any thrombosis and no thrombotic complications were observed during that period. Furthermore, two case series studies reported intravascular hemolysis.<sup>17,18</sup> However, we did not observe significant hemolysis in our case.

In conclusion, ECCO<sub>2</sub>R support, as a less invasive method compared to ECMO, proves to be both an effective and reliable alternative when conventional IMV support is insufficient in cases of acute hypercapnic respiratory failure in the pediatric population. Yet, it should be underscored that ECCOR support is specifically designed for carbon dioxide removal and does not exert any influence on oxygenation. It has been observed that ECCO<sub>2</sub>R can also be utilized in patients with body weights below the recommended range when adequate venous access is available. However, future studies focusing on the pediatric population and the development of standardized guidelines are necessary to better comprehend the clinical significance of the ECCO<sub>2</sub>R procedure.

### Acknowledgments

We thank the patient and her family for their participation in this study.

### Ethical approval

Authors declare that they have written consent from the family.

### Author contribution

The authors confirm contribution to the paper as follows: study conception and design: GÖ; data collection: GÖ, GK, EE; analysis and interpretation of results: GÖ, FD, ABA; draft manuscript preparation: GÖ, GK, EE, FD, ABA. All authors reviewed the results and approved the final version of the manuscript.

### Source of funding

The authors declare the study received no funding.

### Conflict of interest

The authors declare that there is no conflict of interest.

### REFERENCES

- Giraud R, Bendjelid K, Banfi C. Obesity-related respiratory failure: a new area for extracorporeal lung support? *Swiss Med Wkly* 2018; 148: w14651. <https://doi.org/10.4414/sm.w.2018.14651>
- Omecinski K, Cove M, Duggal A, Federspiel W. Extracorporeal carbon dioxide removal (ECCO<sub>2</sub>R): a contemporary review. *Appl Eng Sci* 2022; 10: 100095. <https://doi.org/10.1016/j.apples.2022.100095>
- Combes A, Fanelli V, Pham T, Ranieri VM, European Society of Intensive Care Medicine Trials Group and the "Strategy of Ultra-Protective lung ventilation with Extracorporeal CO<sub>2</sub> Removal for New-Onset moderate to severe ARDS" (SUPERNOVA) Investigators. Feasibility and safety of extracorporeal CO<sub>2</sub> removal to enhance protective ventilation in acute respiratory distress syndrome: the SUPERNOVA study. *Intensive Care Med* 2019; 45: 592-600. <https://doi.org/10.1007/s00134-019-05567-4>
- Burki NK, Mani RK, Herth FJF, et al. A novel extracorporeal CO<sub>2</sub> removal system: results of a pilot study of hypercapnic respiratory failure in patients with COPD. *Chest* 2013; 143: 678-686. <https://doi.org/10.1378/chest.12-0228>
- Schouten LRA, Veltkamp F, Bos AP, et al. Incidence and mortality of acute respiratory distress syndrome in children: a systematic review and meta-analysis. *Crit Care Med* 2016; 44: 819-829. <https://doi.org/10.1097/CCM.0000000000001388>
- Friedman ML, Nitu ME. Acute respiratory failure in children. *Pediatr Ann* 2018; 47: e268-e273. <https://doi.org/10.3928/19382359-20180625-01>
- Yañez LJ, Yunge M, Emilfork M, et al. A prospective, randomized, controlled trial of noninvasive ventilation in pediatric acute respiratory failure. *Pediatr Crit Care Med* 2008; 9: 484-489. <https://doi.org/10.1097/PCC.0b013e318184989f>
- Nishisaki A, Turner DA, Brown CA, et al. A national emergency airway registry for children: landscape of tracheal intubation in 15 PICUs. *Crit Care Med* 2013; 41: 874-885. <https://doi.org/10.1097/CCM.0b013e3182746736>
- Schmidt M, Jaber S, Zogheib E, Godet T, Capellier G, Combes A. Feasibility and safety of low-flow extracorporeal CO<sub>2</sub> removal managed with a renal replacement platform to enhance lung-protective ventilation of patients with mild-to-moderate ARDS. *Crit Care* 2018; 22: 122. <https://doi.org/10.1186/s13054-018-2038-5>
- Giraud R, Banfi C, Assouline B, De Charrière A, Cecconi M, Bendjelid K. The use of extracorporeal CO<sub>2</sub> removal in acute respiratory failure. *Ann Intensive Care* 2021; 11: 43. <https://doi.org/10.1186/s13613-021-00824-6>
- Kluge S, Braune SA, Engel M, et al. Avoiding invasive mechanical ventilation by extracorporeal carbon dioxide removal in patients failing noninvasive ventilation. *Intensive Care Med* 2012; 38: 1632-1639. <https://doi.org/10.1007/s00134-012-2649-2>
- Combes A, Auzinger G, Capellier G, et al. ECCO<sub>2</sub>R therapy in the ICU: consensus of a European round table meeting. *Crit Care* 2020; 24: 490. <https://doi.org/10.1186/s13054-020-03210-z>
- Beloncle F, Brochard L. Extracorporeal Co<sub>2</sub> removal for chronic obstructive pulmonary disease: too risky or ready for a trial? *Crit Care Med* 2015; 43: 245-246. <https://doi.org/10.1097/CCM.0000000000000677>
- Bozkuş F, Bilal B, Öksüz H. Extracorporeal carbondioxide removal (ECCO<sub>2</sub>R): case series and review of literature. *Tuberk Toraks* 2018; 66: 258-265. <https://doi.org/10.5578/tt.26368>
- Del Sorbo L, Fan E, Nava S, Ranieri VM. ECCO<sub>2</sub>R in COPD exacerbation only for the right patients and with the right strategy. *Intensive Care Med* 2016; 42: 1830-1831. <https://doi.org/10.1007/s00134-016-4493-2>
- Cardenas VJ, Miller L, Lynch JE, Anderson MJ, Zwischenberger JB. Percutaneous venovenous CO<sub>2</sub> removal with regional anticoagulation in an ovine model. *ASAIO J* 2006; 52: 467-470. <https://doi.org/10.1097/01.mat.0000227743.07743.5d>

17. Fanelli V, Ranieri MV, Mancebo J, et al. Feasibility and safety of low-flow extracorporeal carbon dioxide removal to facilitate ultra-protective ventilation in patients with moderate acute respiratory distress syndrome. *Crit Care* 2016; 20: 36. <https://doi.org/10.1186/s13054-016-1211-y>
18. Moss CE, Galtrey EJ, Camporota L, et al. A Retrospective observational case series of low-flow venovenous extracorporeal carbon dioxide removal use in patients with respiratory failure. *ASAIO J* 2016; 62: 458-462. <https://doi.org/10.1097/MAT.0000000000000386>
19. Giraud R, Banfi C, Assouline B, De Charrière A, Bendjelid K. Very low blood flow carbon dioxide removal system is not effective in a chronic obstructive pulmonary disease exacerbation setting. *Artif Organs* 2021; 45: 479-487. <https://doi.org/10.1111/aor.13867>