

The importance of transient hypothyroxinemia of prematurity and its controversial management

Ümit Ayşe Tandırcıoğlu¹✉, Serdar Alan¹✉

¹Division of Neonatology, Department of Pediatrics, Kirikkale University Faculty of Medicine, Ankara, Türkiye.

We read the paper on transient hypothyroxinemia of prematurity (THOP) by Maneenil et al.¹ with great interest. They reported the incidence and risk factors of THOP in infants born before 37 weeks of gestation. They found that the incidences of THOP were 39.5%, 8.4% and 4.8% among hospitalized preterm infants born before 28, 34 and 37 weeks of gestation, respectively. According to the study conducted with preterm infants hospitalized in the neonatal intensive care unit (NICU), the risk factors for THOP were being born before the 28th gestational week, having a low Apgar score at 5 minutes, and using aminophylline, dobutamine and morphine treatments.¹ Although the authors did not present treatment data for infants with THOP in the results section, they stated in the discussion section that none of the newborns with THOP required L-thyroxine treatment. There is an ongoing debate as to whether THOP harms the brain development of preterm infants when left untreated. We recently had the chance to manage a case with THOP in our NICU.

Our case with THOP was born via vaginal delivery as a 1330 g male infant at 30^{0/7} weeks of gestation to a 28-year-old mother. Antenatal steroids and tocolytic therapy were administered to the mother at 28 weeks of gestation due to uterine contractions. The infant received intratracheal surfactant due to respiratory distress syndrome (RDS) on the first day of life. He also received ampicillin,

gentamicin, fluconazole, parenteral nutrition and caffeine citrate treatments during the first week of NICU stay. There was no iodine exposure. The free thyroxine (fT4) and thyroid stimulating hormone (TSH) levels of the infant on postnatal day 7 were low, 0.73 ng/dL (0.84-1.76 ng/dL) and 0.685 uIU/mL (0.7-7.9 uIU/mL) respectively. Trends in fT4 and TSH levels between the first and fifth week of life are presented in Fig. 1. Although the TSH level did not reach the normal range yet, fT4 reached the normal range at the postnatal 2nd week of life. In our patient, TSH levels increased in the third week of life, confirming the diagnosis of THOP. Our patient did not have the risk factors mentioned above, identified in the study by Maneenil et al.¹ According to recent data², being born under 31 weeks of gestation and having a diagnosis of RDS were risk factors for our case.

Similar to the cases with THOP in the study by Maneenil et al.¹, our case did not require levothyroxine treatment for THOP. THOP is a condition characterized by low T4 and non-elevated (normal or low) TSH levels in preterm infants.¹⁻⁴ Although several factors contribute to the occurrence of THOP as described above, the main factor is the immaturity of the hypothalamic-pituitary-thyroid axis due to the low gestational age. Indeed, the combination of high TSH and low fT4 values in a newborn is linked to poor neurodevelopmental outcomes.^{3,4} There is still debate on whether THOP harms the developing brain. According to the results of studies involving mainly preterm infants with a gestational age over 30 weeks, THOP has no adverse effect on the developing brain and improves within postnatal 2 weeks.³⁻⁵ Current studies, including extremely preterm infants (under 28 weeks gestation), have shown that

✉ Ümit Ayşe Tandırcıoğlu
aysetandircoglu@gmail.com

Received 19th Oct 2023, revised 30th Nov 2023,
6th Dec 2023, accepted 6th Dec 2023.

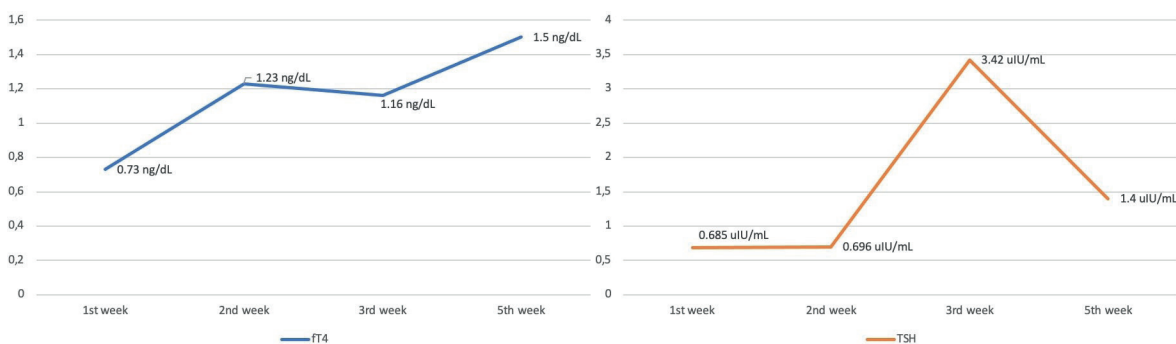


Fig. 1. Thyroid function test screening. fT4: free thyroxine, TSH: thyroid stimulating hormone.

THOP harms the developing brain.⁵ According to our knowledge, prospective randomized trials for treating THOP are lacking. Therefore, there is controversy among clinicians about the indication for treating THOP. More recently, Yoon et al.³ described that the outcomes of THOP were dependent on the severity of the THOP (fT4 <0.5 ng/dL), with infants having more severe THOP showing significantly more adverse short- or long-term outcomes whether they received levothyroxine treatment or not. Our patient did not have severe THOP according to the description of Yoon et al.³ Maneenil et al.¹ had infants with severe THOP in their study cases (the mean fT4 level was 0.63 ± 0.18 ng/dL). A recent retrospective study in our country suggested that clinicians tended to give levothyroxine treatment to the group with a median gestational age of 28 weeks, while levothyroxine treatment was not necessary for older preterm infants (median 31 weeks).⁴ Maneenil et al.¹ did not present any data on the prognosis of untreated THOP infants born below 28 weeks of gestation (n: 17). Our patient, who did not develop any problems related to prematurity, is now two months old and neurodevelopmental follow-up is ongoing in our outpatient department.

If Maneenil et al.¹ could present the short and/or long-term results of THOP cases that did not require treatment, they would have made a valuable contribution to the controversial treatment literature of THOP.

Author contribution

The authors confirm contribution to the paper as follows: Study Conception and Design: UAT, SA, Drafting of the manuscript: UAT, SA, Critical revision: SA. All authors approved the final version of the manuscript.

Source of funding

The authors declare the study received no funding.

Conflict of interest

The authors declare that there is no conflict of interest.

REFERENCES

1. Maneenil G, Juthong M, Thatrimontrichai A, Janjindamai W, Dissaneevate S, Jaruratanasirikul S. Incidence and risk factors of transient hypothyroxinemia of prematurity: a prospective cohort study. *Turk J Pediatr* 2023; 65: 562-571. <https://doi.org/10.24953/turkjped.2023.94>
2. Campos-Martorell A, Ramon AM, Barros KN, et al. Thyroid Function in 509 Premature Newborns Below 31 Weeks of Gestational Age: Evaluation and Follow-up. *J Clin Res Pediatr Endocrinol* 2022; 14: 453-462. <https://doi.org/10.4274/jcrpe.galenos.2022.2022-2-1>
3. Yoon SA, Chang YS, Yang M, et al. Effect of levothyroxine supplementation in extremely low birth weight infants with transient hypothyroxinemia of prematurity. *Sci Rep* 2022; 12: 9717. <https://doi.org/10.1038/s41598-022-13927-2>

4. Yilmaz A, Ozer Y, Kaya N, et al. Clinical indicators that influence a clinician's decision to start L-thyroxine treatment in prematurity with transient hypothyroxinemia. *Ital J Pediatr* 2023; 49: 105. <https://doi.org/10.1186/s13052-023-01516-6>
5. Iijima S. Current knowledge of transient hypothyroxinemia of prematurity: to treat or not to treat? *J Matern Fetal Neonatal Med* 2019; 32: 2591-2597. <https://doi.org/10.1080/14767058.2018.1441277>